ANIL AGGRAWAL'S
Internet Journal of Forensic Medicine and Toxicology
The world's first online journal devoted entirely to forensic medicine and toxicology · Published 1 January and 1 July

VOL. 4, NO. 2 · JULY – DECEMBER 2003
Downloaded from www.anilaggrawal.com · ISSN 0972-8074 (Online) · https://www.anilaggrawal.com/ij/vol_004_no_002/papers/paper006.html

Homicidal Electrocution - A Medicolegal Rarity

Luv Sharma, Vijay P. Khanagwal, Basant Lal Sirohiwal, P.K. Paliwal, D.R. Yadav

Lecturer, Department of Forensic Medicine, Pt. B.D. Sharma Postgraduate Institute of Medical Sciences, Rohtak-124001, Haryana, India
Reader, Department of Forensic Medicine, Pt. B.D. Sharma Postgraduate Institute of Medical Sciences, Rohtak-124001, Haryana, India
Associate Professor, Department of Forensic Medicine, Pt. B.D. Sharma Postgraduate Institute of Medical Sciences, Rohtak-124001, Haryana, India
Professor & Head, Department of Forensic Medicine, Pt. B.D. Sharma Postgraduate Institute of Medical Sciences, Rohtak-124001, Haryana, India
Contact: the corresponding author Luv Sharma · drluvksharma@yahoo.com

CITE THIS ARTICLE

Sharma L, Khanagwal VP, Sirohiwal BL, Paliwal PK, Yadav DR. Homicidal Electrocution - A Medicolegal Rarity. *Anil Aggrawal's Internet Journal of Forensic Medicine and Toxicology* [serial online], 2003; Vol. 4, No. 2 (July – December 2003): []. Available from: https://www.anilaggrawal.com/ij/vol_004_no_002/papers/paper006.html

ABSTRACT

Homicidal electrocution is a very uncommon (or perhaps under reported) phenomenon - more so in India where reporting of any manner of death is anyway scarce. This type of murder envisages a picture of a very ruthless offender, the crime itself being premeditated and planned. Passage of electric current through the human body is an aberration, and commission of such an act purposefully is diabolical. The present paper deals with the murder of two elderly Sikh gentlemen by their rival claimants for a piece of land. This situation (killing of people for land) is very common in rural India. However the unusual aspect in this case was the manner in which the murder was committed (the use of domestic electric supply)..

Keywords: Electric Deaths, Murder, Homicidal electrocution

Introduction



Figure 1. Photograph showing the dead body of the granthi (Victim 1) before autopsy (notice suffused and blood stained face) and prominent marbling over the thorax.

Notwithstanding innumerable *modus operandi* of procuring violent deaths utilized in our country; electricity is a rare and unusual method for homicidal means. Very few cases have been reported in this context.

Deaths due to electrocution are infrequent. Virtually all such deaths are accidental in nature with suicides much rarer and homicides least common. Deaths due to electrocution virtually always involve alternating current, it being more commonly used in this country. Another factor could be that humans are about 4-6 times more sensitive to alternating than to direct current.

The most common method of homicide with electrical current is to drop a "live" (plugged-in) electrical device into a bath tub when an individual is taking a bath. There are usually no electrical burns in such a case and if the device is subsequently removed, the cause of death can not be determined (Dimaio DJ and Dimaio VJM, 1993).

As observed by Knight (1991) homicide is occasionally committed by electricity. He reported a typical bath death of a woman with an electric fan heater immersed in the bath tub by her husband. He had borrowed the book "*The Do-It-Yourself Home Electrician*" from the public library the previous day!



Figure 2. Entry site of electrical current over top of forehead with characteristic crater formation (Victim 1).

Another notable homicide reported by Knight concerned the wrapping of bare electrical wires around a women's neck by her husband. This wire was a thick 30 amp cooker cable with 40 cm of insulation stripped except for the extreme tips. Although he gave a very unlikely explanation for this (he was using this wire to test his electric shaver!), he could not be prosecuted for lack of evidence.

Cox (1998) notes that the vast majority of electrocutions are accidental in origin but a few are suicidal and the circumstances are usually obvious. Occasionally homicide may be perpetuated by electrocution.

The rarity of electrocution used for procuring homicide is also noted by the Indian commentator Modi (1996). He comments, "homicide by electricity through extremely rare is quite possible". Another Indian author, Parikh (1986) comments that "homicide though rare is possible. An electrical shock may be given in malice!"

Recorded homicidal electrocutions are scarce to find. Polson (1985) quotes a case in which a husband attached the household supply switch ingeniously to a soap dish used by his wife. The same case was also reported by Taylor (1984). Carrieri (1957) also recorded the murder of a women by her husband by electrocution.



Figure 3. Elongated contact wounds of electricity seen over palmer aspect of thumb with raised, everted and thickened margins (Victim 1).

Bornstein (1962) quotes a father who murdered his 22 month old son by inflicting repeated electrical shocks with bared wires of a radio flex attached to the crib. Many peculiar marks were observed on the child during autopsy some of which were tiny and pin point, others being elongated up to 4 cms in length. They appeared to have been produced by pointed agents. The appearances were those of repeated application of ends of pointed wires.

The cases that we examined showed remarkable similarities to the above mentioned case though the victim's age was on the other extreme.

Case History

Two bodies of elderly Sikh gentlemen were brought to our mortuary for postmortem examination. We inferred from the history narrated by the police and relatives of the victims that one of them was an unmarried *granthi* (*granthi* is a Sikh priest presiding over a Sikh place of worship called the *Gurudwara*) and was in charge of the *Gurudwara* where both bodies had been discovered. The other victim was an old widower (85 year old) who was a friend of the *granthi* and slept along with him in the *Gurudwara*. Both were in the habit of sleeping in an open courtyard in the *Gurudwara* compound on cots. The police alleged that the two had died of electrocution but were silent on the manner of death. They had recovered small pieces of insulation material of wires which had been cut by a sharp blade. No intact wire was found and the source of electricity was a main power switch located about 6-7 feet away from the cots.



Figure 4. Similar elongated contact wounds of electricity over dorsal aspect of the hands (Victim 1).

The relatives of the widower alleged that the real owner of the land on which the *Gurudwara* stood had killed both men as the *granthi* was not ready to hand over the land back to them.

Postmortem examination

The bodies were of two old *Sikhs*, the bodies had cooled down to room temperature; rigor mortis was in the passing off phase and post mortem hypostasis was fixed on the back. Marbling could be seen over both shoulders and over the anterior chest wall.

Injuries observed

These were of two types i.e. entry and exit contact burns of electrocution. The entry points of electrocution were in the form of oral grayish craters of size varying from 0.5x0.5 to 2x0.5 cm which were elongated with the craters depressed and margins raised, everted and thickened. The floor of each wound was pale, healthy and ridges of elevated skin were hyperemic. These were present over palmar aspects of the hands, lateral aspects of middle and proximal phalanges the forearms (medial aspects of all fingers) and dorsal aspects of the hands. The tissues in the vicinity showed coagulative necrosis. The burns were placed in transverse or vertically oblique directions. On the body of the *granthi* an oval crater was observed in the center of the upper margin of the forehead.

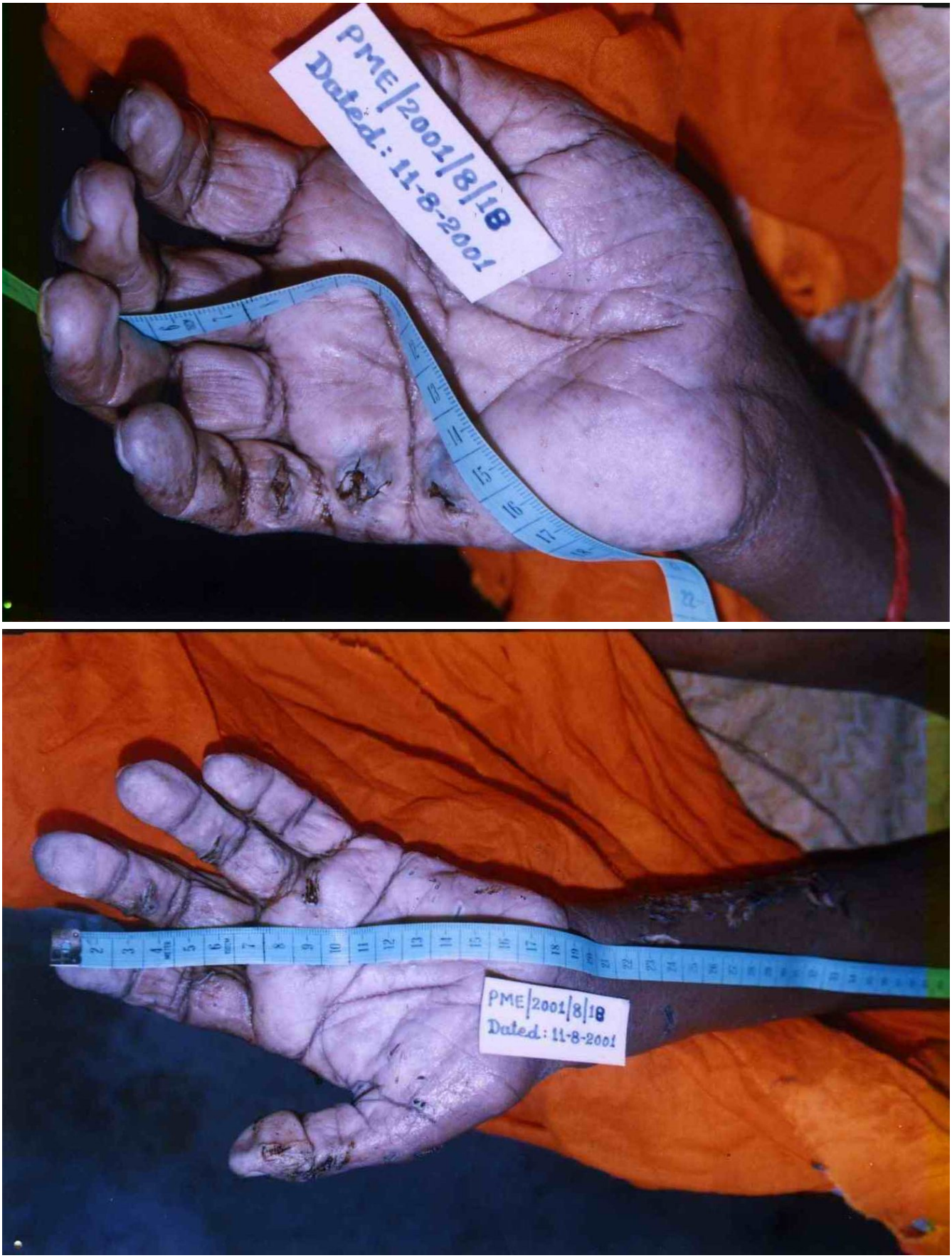

Figure 5 (top and bottom). Multiple entry contact wounds of electricity seen over palmer aspects of hands (both right and left) which are crater like, elongated, raised, everted margins thickened (Victim 2).

There were multiple exit electrical burns of size between 1x0.5 to 2x1 cm on the plantar aspects of both feet in the anterior 1/3rd and in between toes with everted margins in the form of punctured wounds and with disruption of tissues showing ecchymosis.

We concluded that the two victims had been subjected to repeated electrical shocks by bared wires (cutoff insulation was found scattered in the compound) and had died on account of this electrocution, the manner of which was homicidal.

Police inquiries and offender's submission

Meanwhile the police was searching for the accused absconders. Within a fortnight of these double murders they caught the 4 sons of the landlord who had gifted the land to the *granthi* for the *Gurudwara* (their apprehension was possible due to a tip off and the confessions of their widowed mother who bore a grudge against the *granthi*). They confessed of torturing the two victims by applying naked (bared) wires to their bodies which had been connected to the power switch on the wall. It took 6 men to overpower and silence the victims.

The court convicted them of murder of the first degree and their appeals were also turned down in the higher courts.

Conclusion

As detailed above, this was a rare case of homicidal electrocution, the victims were aged and were asleep when attacked. The circumstances of the case, the crime scene, the presence of multiple electrical burns on the body and most importantly a clear motive for this crime helped us to conclude that the case was one of homicidal electrocution. It is ironical that the use of live bared wires snuffed out the life of two unfortunate men and added another case of to the literature of homicidal electrocution.



Figure 6 (top and bottom). Multiple exit contact wounds (a) electricity seen over sole of and (b) both feet seen as puncture wounds with everted margins (Victim 2).

References

1. Diomaio DJ, Dimaio VJM. Forensic Pathology. Boca Raton: CRC Press; 1993: pp.367-9, 371.
2. Knight B. Forensic Pathology. London: Edward Arnold; 1991: pp.300-01, 303.
3. Knight B, Cox HMW. Medical Jurisprudence and Toxicology. 6th ed. Allahabad: The Law Book Co.(P) Ltd.; 1998: pp.406-7.
4. Knight B (editor). Simpson's Forensic Medicine. Xth ed. Serenoak Kent: Edward Arnold; 1991; pp.224, 232-3.
5. Subramanyam BV (editor). Modi's Textbook of Medical Jurisprudence and Toxicology. 22nd ed. 1999: pp.243, 248.
6. Parikh CK. Parikh's Textbook of Medical Jurisprudence and Toxicology. IV ed. Bombay: Medico legal Center; 1986: pp.386.
7. Polson CJ. The essentials of Forensic Medicine. 4th ed. Oxford: Pergamon Press; 1985: pp.306.
8. Mant AK. Taylor's Principles and practice of Medical Jurisprudence. 23rd ed. Edinburgh: Churchill Livingstone; 1984: pp.274.