ANIL AGGRAWAL'S
Internet Journal of Forensic Medicine and Toxicology
The world's first online journal devoted entirely to forensic medicine and toxicology · Published 1 January and 1 July

VOL. 4, NO. 2 · JULY – DECEMBER 2003
Downloaded from www.anilaggrawal.com · ISSN 0972-8074 (Online) · https://www.anilaggrawal.com/ij/vol_004_no_002/papers/paper007.html

Skull acting as a container for the crime bullet - A case report of a skeletonized body

P.K. Paliwal, Basant Lal Sirohiwal, Vijay P. Khanagwal, Luv Sharma, D.R. Yadav

Associate Professor, Department of Forensic Medicine, Pt. B.D. Sharma Postgraduate Institute of Medical Sciences, Rohtak-124001, Haryana, India
Reader, Department of Forensic Medicine, Pt. B.D. Sharma Postgraduate Institute of Medical Sciences, Rohtak-124001, Haryana, India
Lecturer, Department of Forensic Medicine, Pt. B.D. Sharma Postgraduate Institute of Medical Sciences, Rohtak-124001, Haryana, India
Professor & Head, Department of Forensic Medicine, Pt. B.D. Sharma Postgraduate Institute of Medical Sciences, Rohtak-124001, Haryana, India
Contact: the corresponding author Luv Sharma · drluvksharma@yahoo.com

CITE THIS ARTICLE

Paliwal PK, Sirohiwal BL, Khanagwal VP, Sharma L, Yadav DR. Skull acting as a container for the crime bullet - A case report of a skeletonized body. *Anil Aggrawal's Internet Journal of Forensic Medicine and Toxicology* [serial online], 2003; Vol. 4, No. 2 (July – December 2003): []. Available from: https://www.anilaggrawal.com/ij/vol_004_no_002/papers/paper007.html

ABSTRACT

A skeletonized body recovered from a running canal water was referred to the Deptt. of Forensic Medicine, Pt. B.D.Sharma PGIMS, Rohtak. The police made it to be a case of death due to strangulation after investigation. Some villagers identified the skeletonized body on the basis of belongings - clothes, watch etc. as their relative - a 50 year old male. The perpetrator was caught by bullet being present within the skull of the victim, the skull acting as a safe container for it.

Keywords: Ballistics, Crime bullet, Entry wound, Firearms

Brief History



Figure 1. Skeleton which was recovered from the canal.



Figure 2. Entrance wound of a rifled firearm ammunition on left temporal bone.

A male, 50 years of age was missing from his house with effect from 31.7.1998. An unknown skeletonized body was found on 13.10.1998 in running canal water. It was widely suspected to be the body of that missing male. There was an alleged history of his having been involved in a quarrel with his neighbor.

Post mortem examination with discussion

The skeletonized body was examined (Illustration-I). Opinion was given regarding age, sex, nature of bones, stature, time since death etc. But the most interesting observation was in relation to the cause of death.

A conspicuous finding clearly visible on the skull - which was naturally macerated - was the presence of three holes. These were missed by the relatives and the police. Perhaps they took them for some natural orifices. The skull showed three holes on it, which were as follows. (Illustration-2 & 3)



Figure 3. Two firearms on the right side of the skull. One of them is the entrance wound and the other is the exit wound. A total of three firearms wounds indicated that at least one bullet must be there within the skull.

i) An entrance hole of a rifled firearm ammunition 0.7x 0.5cms on (left) temporal bone 13.5 cms away from midline and 1.5 cms above the back aspect of left zygomatic arch and 5.5 cms antero superior to lower extremity of mastoid process (Illustration-2).

ii) An irregular rifled firearm ammunition exit hole 18x12 mm in size situated over the back aspect of right parietal bone 9 cms away from midline and 8 cms posterior superior to the inferior extremity of right mastoid process (Illustration-3).

iii) An entrance hole of rifled firearm ammunition 0.7x0.5 cms on the right temporal bone 13 cms. away from midline 5 cms. from mastoid process and 1.5 cms above the posterior extremity of right zygomatic arch.

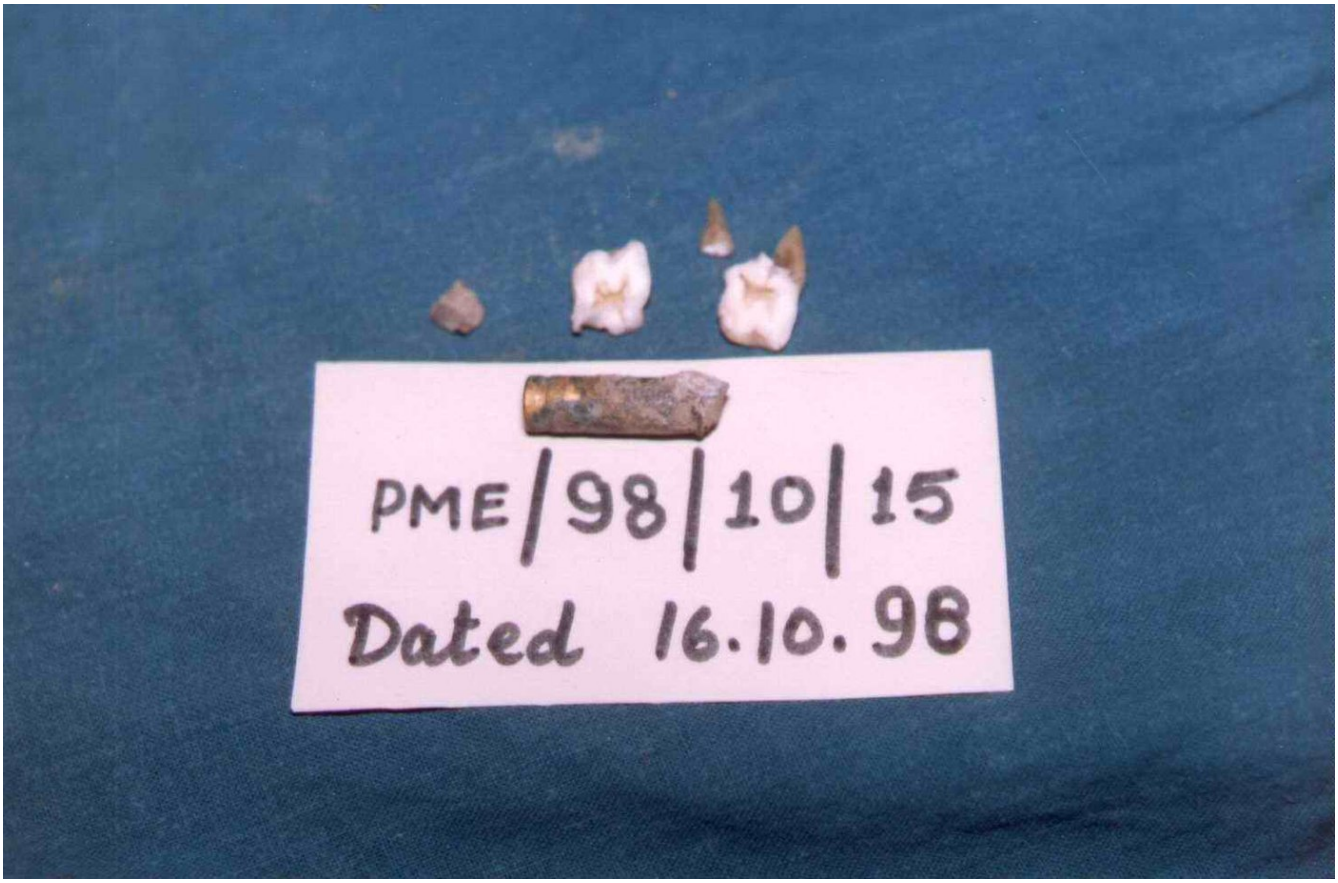

Figure 4. The evidence bullet found within the skull. It was this bullet which nailed the culprit.

Since there were 3 firearm holes in the skull, the principle of odd and even rule applied, i.e. there had to be a bullet inside the skull. The bullet was duly searched for. It was found within the cranial cavity. Brain matter was missing but the crime bullet remained inside the cranial cavity, the skull acting rather as a container for the crime bullet. This bullet could not get out even in the running water. The criminal could have never thought that the skull would act as a container of their crime bullet and will result into their being caught. The bullet was sent for ballistic examination. An examination of the firearm recovered from the suspect (the neighbor with whom the dead man was supposed to have fought) proved beyond doubt that the crime bullet was fired from that firearm. Based on these findings, the suspect was convicted.

Conclusion

In this interesting case, the skull acted as a container of crime bullet even after a lapse of considerable time, and that too in running water of a canal. Thus the natural anatomy of the skull played its role for catching the criminals.