ANIL AGGRAWAL'S
Internet Journal of Forensic Medicine and Toxicology
The world's first online journal devoted entirely to forensic medicine and toxicology · Published 1 January and 1 July

VOL. 4, NO. 2 · JULY – DECEMBER 2003
Downloaded from www.anilaggrawal.com · ISSN 0972-8074 (Online) · https://www.anilaggrawal.com/ij/vol_004_no_002/papers/paper008.html

Pieces of tooth solve the mystery of identity in a case of murder - A case of reconstructive forensic medicine

J. N. Soni

Professor & Head, Department of Forensic Medicine, G. R. Medical College & J. A. Hospitals, Gwalior, Madhya Pradesh, India

Contact: the corresponding author J. N. Soni · sonidrjn@yahoo.com

CITE THIS ARTICLE

Soni JN. Pieces of tooth solve the mystery of identity in a case of murder - A case of reconstructive forensic medicine. *Anil Aggrawal's Internet Journal of Forensic Medicine and Toxicology* [serial online], 2003; Vol. 4, No. 2 (July – December 2003): []. Available from: https://www.anilaggrawal.com/ij/vol_004_no_002/papers/paper008.html

ABSTRACT

This is a case illustrating the application of reconstructive forensic medicine. A dead body and a few pieces of broken teeth were recovered at different places. By reconstruction of the skull, it could be proved that both belonged to the same person, thus obviating the need for costly DNA profiling. In any case, DNA profiling was a doubtful proposition since the bones and teeth were quite old, and were exposed to hot and humid atmosphere for a very long period.

Keywords: Forensic odontology, forensic dentistry, identification, homicide, corpus delicti

Case Report



Figure 1. Dead body found in the well.



Figure 2. Seventh cervical vertebra showing a cut on its anterior aspect.

A middle aged male person was working in his fields. From there some criminals abducted him. There was a widespread belief that he was murdered. After ten days, his body was recovered from a dry well (PHOTO-1). The local police also brought few pieces of teeth, which were recovered from a spot somewhat away from where the body was found. The police also found multiple blood stains present at the spot, where the teeth were found. One of the questions which had to be answered was whether the teeth belonged to the same individual or to some other individual.

The decomposed and partially skeletonized dead body was referred from a peripheral medical center to the department of forensic medicine, G. R. Medical college, Gwalior, Madhya Pradesh. On examination, a body sharp cut was found on the 7th cervical vertebrae on its frontal aspect, which ran from above downwards (Photo-2).



Figure 3. Skull with the two broken teeth.

In the picture on the left, one can see all seven cervical vertebrae, and the first thoracic vertebra which were rearranged (and threaded on a paper roll) in the anatomical position for better appreciation of the injury. On extreme right of the picture is the first cervical vertebra (Atlas), and on extreme left is the first thoracic vertebra. An arrow depicts the cut on the seventh cervical vertebra. It indicated that the cause of death could be a stab wound of the neck, which is a common method of murder in this area.

The right lateral incisor and right canine teeth were broken, with their proximal parts still present in their corresponding sockets (PHOTO-3). The broken pieces of teeth recovered from the spot (Photo-4) were articulated & reconstructed (Photo-5). The reconstructed teeth were then placed on the remains of the teeth within the socket. There was a perfect and snug geometrical match. The probability that such a perfect match could be obtained from broken pieces of teeth from two different individuals was very minuscule indeed.


P.M. No. 1000
31.10.01

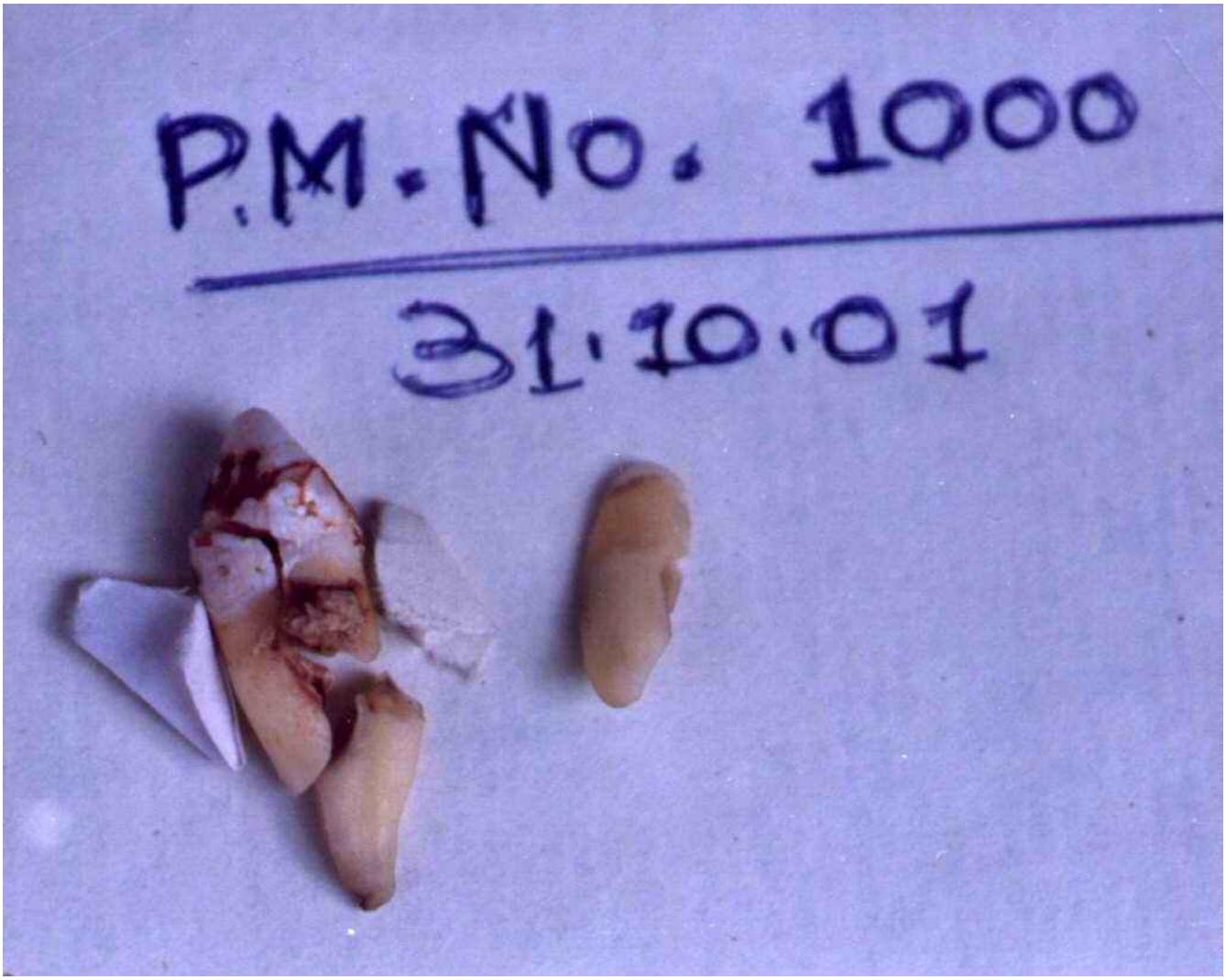

Figure 4 (above). Recovered pieces of broken teeth and (below) reconstructed teeth. These fit snugly into the skull above.

Thus by reconstructive methods, the pieces of teeth recovered from the spot, proved to be of the same individual. This indicated that the individual was perhaps attacked at the spot where the teeth were found. This resulted in breaking of the teeth, and associated bloodshed. After causing these injuries, the body was disposed of in the well to hide the corpus delicti. However trace elements in the form of pieces of teeth helped to piece together the mystery.

Conclusion

This is a case of alertness of investigating agencies and careful examination by the autopsy surgeon . The role of reconstructive forensic medicine is highlighted in the case.