ANIL AGGRAWAL'S
Internet Journal of Forensic Medicine and Toxicology
The world's first online journal devoted entirely to forensic medicine and toxicology · Published 1 January and 1 July

VOL. 26, NO. 2 · JULY – DECEMBER 2025
Downloaded from www.anilaggrawal.com · ISSN 0972-8074 (Online) · https://www.anilaggrawal.com/ij/vol_026_no_002/papers/paper001.html

Forensic Interpretation and Importance of Pathologic Findings in an Unusual Case of Hanging

Ivan Tsranchev[1*], Pavel Timonov[1], Iliana Toneva[1], Antoaneta Fasova[1], Elizabet Dzhambazova[1], Petar Uchikov[1]

[1]Medical University of Plovdiv, Republic of Bulgaria, Europe

* Corresponding author: Ivan Tsranchev, Medical University of Plovdiv, Republic of Bulgaria, Europe · tsranchev@inbox.ru

CITE THIS ARTICLE

Tsranchev I, Timonov P, Toneva I, Fasova A, Dzhambazova E, Uchikov P. Forensic Interpretation and Importance of Pathologic Findings in an Unusual Case of Hanging. *Anil Aggrawal's Internet Journal of Forensic Medicine and Toxicology* [serial online], 2025; Vol. 26, No. 2 (July – December 2025): [about 6 p]. DOI: 10.5281/zenodo.15708563. Available from: https://www.anilaggrawal.com/ij/vol_026_no_002/papers/paper001.html

ABSTRACT

Hanging is one of the most common methods of suicide worldwide, accounting for more than 50% of the population regardless of gender. In addition to being a method of suicide, hanging may also occur postmortem as an attempt to conceal a crime. Therefore, it is important to carefully examine the body and search for typical signs of this type of mechanical asphyxia, as well as for specific pathologic indicators confirming the exact cause, mechanism, and manner of death. The presented case report shows that a concealed homicide must be considered in every hanging victim, which requires a thorough investigation of the scene of death, which could give crucial information about the circumstances, with further important autopsy examination of the body externally and internally, and additional toxicological and histological examination, helping coroners to resolve the case and confirm the exact cause, manner, and mechanism of death.

Keywords: hanging, suicide, obstruction of orifices, concealed homicide, cause of death, manner of death

Introduction

Asphyxia generally refers to the deprivation of tissues and organs of oxygen due to mechanical or chemical factors, accompanied by an accumulation of carbon dioxide [1, 2]. Mechanical asphyxia is caused by obstruction along the respiratory pathways, which can occur by neck compression, chest compression, obstruction of airway paths, or lack of environmental oxygen [3, 4]. In cases of neck compression, there are three main types of asphyxia: hanging (most common in suicides), ligature

strangulation (most commonly associated with attempted murder), and manual strangulation (typical homicide) [5, 6]. The last could be in combination with other mechanical asphyxia – obstruction of the mouth and/or nose of the victim.

There are no pathognomonic signs for the different types of mechanical asphyxia. Still, the correct interpretation of all findings that are specific to one or another type of mechanical asphyxia collected from the crime scene and the corpse examination allows coroners to make an accurate conclusion about the cause, manner, and even mechanism of death. The following case report illustrates the points discussed above, demonstrating how the presence of classic external and internal features in hanging could be crucial in determining whether death was due to obstruction of the mouth and nose or hanging.

Case Presentation

The body of a 60-year-old man was found hanging in the basement of his house in a block near the town of Pazardjik, Pazardjik district, Republic of Bulgaria. The cellar was locked from the inside with a key that was installed on the lock; no signs of foul play were found at the scene. A white rope was hung from the ceiling of the cellar, and a ligature was made of it, encircling the deceased's neck.

The body was hung so that the face was pressed against the surrounding wooden shelves, which were part of the room's interior (Figure 1). No suicide note was found at the scene, but according to relatives, he was depressed due to severe financial problems.

The body was sent for a routine autopsy in order for the cause, manner, and mechanism of death to be established. The following findings were present during the external examination of the body: well-developed and fixed lividities, situated mainly on the lower parts of the body and encircling the lower limbs. The neck examination showed the presence of two ligature marks (Figure 2).



Figure 1 -1 showing the position of the corpse at the crime scene



Figure 2 -2 showing both the ligature marks around the neck region



Figure 3 -3 showing the traumatic changes over the lower lip

The upper ligature mark was well presented, situated above the level of the thyroid cartilage, with a point of suspension located on the left occipital area of the head. The second ligature mark was presented as an additional furrow situated below the first one, again above the level of thyroid cartilage, visible on the frontal and right aspects of the neck.

A slit-like laceration was present on the chin, measuring approximately 3 cm with a depth of 0.5 cm. The margins of the wounds were irregular, bruised, and abraded. Tissue bridges were found in the depth of the wound. Multiple irregularly shaped abrasions were found on the skin of the lower lip (Figure 3).

These abrasions had dry, reddish surfaces and did not have scab formation. On the mucosa of the upper lip, two blue bruises with oval shapes and equal size (1 x 2 cm) were visible on the left and the right, while on the lower lip, there were four slit-like lacerated wounds following the line of the dental crowns (Fig. 4).



Figure 4 -4 showing the lacerations on the mucosa of the lower lip

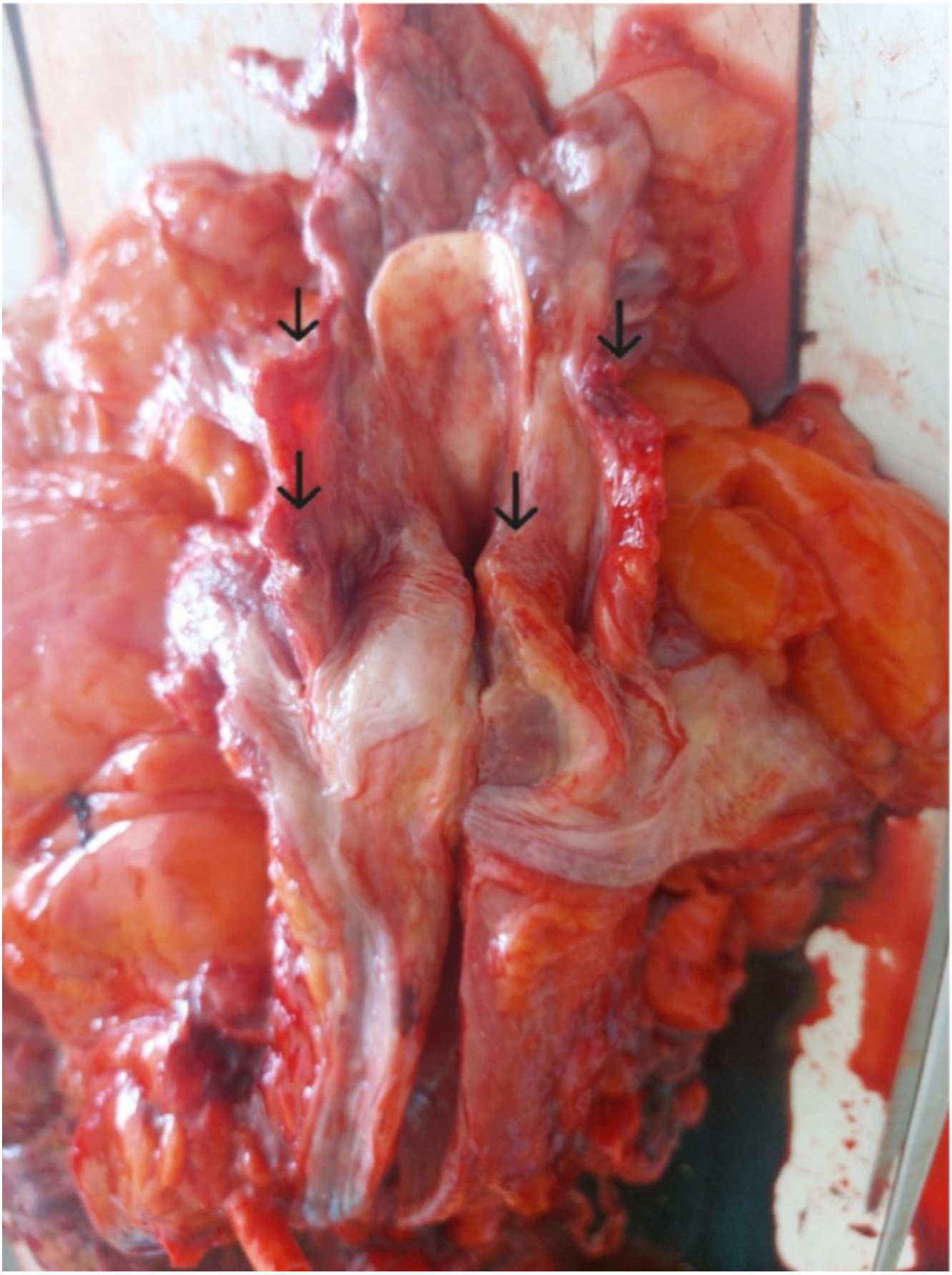

Figure 5 -5 showing fractures in both the upper horns of the thyroid cartilage and the hyoid bone

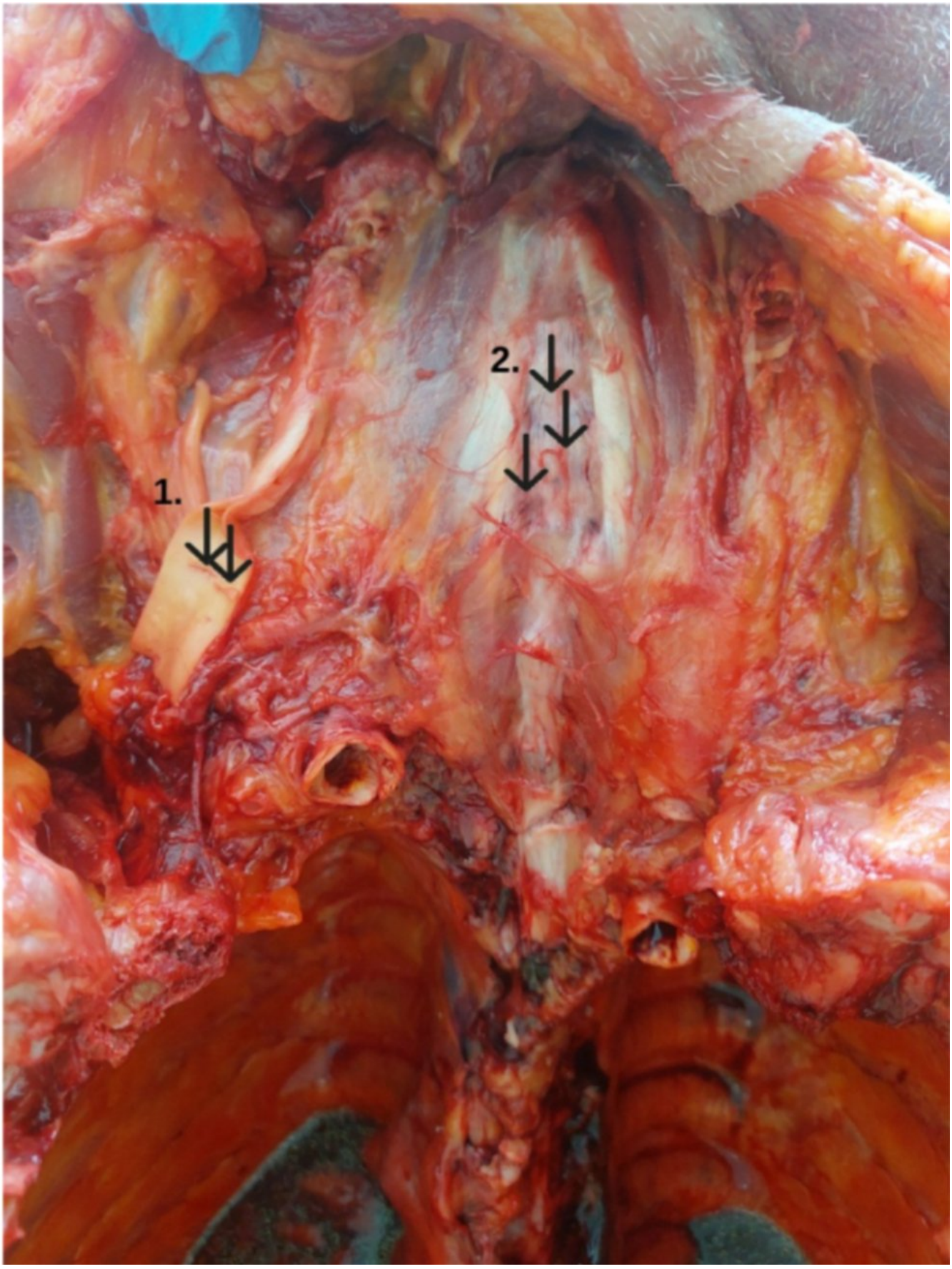

Figure 6 -6 showing 1. Amussat's sign and 2. Simon's bleeding

In the left cheek area, there was a patchy bruise measuring 6 x 4 cm. The oronasal passages were not obstructed and clear. The right elbow had a patchy abrasion with a dry reddish surface,

measuring 1 x 1.5 cm. A similar abrasion was noted on the middle third of the right forearm. On the front of the left knee, there was a bluish bruise measuring 2 x 2.5 cm. No other traumatic injuries were present on the deceased body.

Internal examination: The internal examination of the neck showed that the upper horns of the thyroid cartilage and the hyoid bone were fractured bilaterally, with haemorrhages in the surrounding tissues (Fig. 5).

Subcutaneous haemorrhages were observed beneath the ligature mark. Well- defined haemorrhages of the neck muscle (superficial and deeply situated ones) were present. Amussat's sign (arrow 1 in the figure) was represented by linear transverse tearing on the intima of the right carotid artery (see Figure 6) in combination with Simon’s bleeding (arrow 2 in the same figure). Both lungs were congested and oedematous with multiple dot-like subpleural petechial haemorrhages.

The toxicology results were negative for alcohol and drugs. No other traumatic injuries were observed over the body, externally or internally.

Samples from internal organs were taken, glass slides with H-E staining were generated, and additional microscopic examination was performed with a Zeiss PrimoStar microscope with zooms of x10, x40, and x100. Organs showed well- presented stasis, oedema, and petechial haemorrhages. Skin samples from ligature marks showed evidence of vitality – haemorrhages into the true dermis with inflammatory white cells in depth.

Based on all autopsy findings and all performed additional examinations, the cause of death was determined as mechanical asphyxia due to hanging.

Discussion

There are no pathognomonic signs to distinguish the different types of mechanical asphyxia. Hanging can result from homicide, suicide, or an accident. Cases of suicide by hanging are the most frequently described in the literature, accounting for around 95 % of all cases. In contrast, cases of homicide by hanging are rare [7]. The reasons for committing suicide vary – mental disorders, personal dissatisfaction with life, or the onset of a malignant disease threatening the patient’s life. These rare tumours often appear at a young age [8]. It is more typical to see the concealment of a committed murder, where the victim is hanged after death in an attempt to simulate suicide. Accidental cases are usually seen in cases of autoerotic asphyxia [9-13].

The determination of whether death is the result of homicide, suicide, or accident is based on findings at the scene (the position of the body related to the surrounding interior), specific autopsy findings, and additional toxicological results. In the presented case, the presence of two ligature marks and only one ligature material could be explained by the body slipping during the convulsive phase, typical for death caused by mechanical asphyxia, or as an alternative possible mechanism of production - by an initial incomplete process of hanging attempt in a close time interval. The cause of death was attributed to mechanical asphyxia due to hanging. The conclusion was made by the presence of the following characteristics of vital injury: bilateral fracture of upper horns of the thyroid cartilage and hyoid bone, bruising of the neck muscles, and tears in the intima of the carotid arteries (Amussat’s sign). Another possible finding that could be observed in cases of hanging is the so-called “Simon’s bleeding”, referring to stripe-like haemorrhages on the ventral surface of the intervertebral discs of the lumbar part of the spinal column [14-17]. All these vital

morphologic features seen over the cadaver during the coroner's examination play essential roles as evidence for the vitality of the occurred mechanic asphyxia and as predictors of the exact mechanic asphyxia type – especially hanging, not mechanic obstruction of orifices [18-21]. The abrasions and bruises on the limbs and traumatic changes around the face and oral cavity are a result of the body interacting with the shelves during the convulsive phase. Some injuries, especially oral lacerations, could be, in rare cases, incompatible with life due to following aspiration of blood, and the patient would not survive even if found alive due to a hypoxic state. The changes occurring in the damaged tissues are irreversible, and they lose their function [22]. Imaging studies are also highly informative regarding the type and mechanism of the injury [23]. The presence of typical vital markers for death occurring by hanging in combination with all other features, achieved by the crime scene examination and additional microscopic and toxicologic analysis, excludes another type of asphyxiation in the recent case and confirms the mechanism, manner, and cause of death.

Given the scene findings, autopsy findings, and additional laboratory findings, the hypothesis of suicide is accepted from an expert point of view.

Conclusion

Determining the manner of death in a case of hanging is not always such an easy expert task. The presented case report shows that a concealed homicide must be considered in every hanging victim, which requires a thorough investigation of the scene of death, which could give crucial information about the circumstances. Knowing and searching for the classic external and internal morphologic signs of death by hanging still plays a vital role in determining the expert answers about the cause, mechanism, and manner of death in doubtful clinicopathologic cases, while the correct forensic diagnosis plays its crucial role in the process of crime investigation by a criminal point of view.

References

1. Stoicho R. Forensic Medicine and Deontology, 2006
2. Gautam B. Review of Forensic Medicine and Toxicology. 2012
3. Wyatt JP. Oxford handbook of forensic medicine. Oxford: Oxford University Press; 2011.
4. Hausfeld JN, Yanagisawa E, Pensak ML. Sudden Airway Obstruction Due to Pedunculated Laryngeal Polyps. Annals of Otology, Rhinology & Laryngology. 1983 Jul;92(4):340–3.
5. Biliana Mileva, Kiryakova T, Nikolov D, Alexandrov A. NEONATICIDE – LIGATURE STRANGULATION OF A NEWBORN. DOAJ (DOAJ: Directory of Open Access Journals). 2019 Dec 1;
6. Nikolov D, Brainova-Michich I, Goshev M, Alexandrov A, Hristov S. A case of neonaticide - manual strangulation of a newborn. Science and Technologies [Internet]. 2015;V(1):310–3. Available from: https://www.sustz.com/journal/VolumeV/Number1/Papers/DimitarNikolov.pdf
7. Gunnell D, Bennewith O, Hawton K, Simkin S, Kapur N. The epidemiology and prevention of suicide by hanging: a systematic review. International Journal of Epidemiology. 2005 Jan 19;34(2):433–42.
8. Kiskinov PI, Palavurov AM, Mollova-Kyosebekirova AY, Atliev KT, Zanzov EI, Anastasova VN. Unique Case of Rare Non-Neural Granular Cell Tumor of the Rectus Abdominis Muscle. Medicina. 2024 Mar 31;60(4):576.

9. Lohner L, Sperhake JP, Püschel K, Schröder AS. Autoerotic Deaths in Hamburg, Germany: Autoerotic accident or death from internal cause in an autoerotic setting? A retrospective study from 2004-2018. Forensic Science International. 2020 Aug;313:110340.
10. Tzikas A, Kornappel S, Püschel K. Autoerotic deaths and low socioeconomic status. Rechtsmedizin. 2016 Jan 13;26(1):53–5.
11. Idota N, Nakamura M, Tsuboi H, Ichioka H, Shintani-Ishida K, Ikegaya H. Autoerotic asphyxia using a plastic bag loosely covering the head over a gas mask. Legal Medicine. 2019 May;38:69–72.
12. Mileva B, Goshev M, Alexandrov A, Gitto L. The shame of truth – death due to accidental autoerotic asphyxia. Medico-Legal Journal. 2022 Sep 15;002581722210861.
13. Brainova-Michich I, Goshev M, Alexandrov A, hristov S. A case of accidental death due to autoerotic asphyxiation. Science and Technologies. 2015;V(1):320–2.
14. Hejna P, Rejtarová O. Bleedings into the anterior aspect of the intervertebral disks in the lumbar region of the spine as a diagnostic sign of hanging. 2010 Mar 1;55(2):428–31.
15. Tawil M, Serenella Serinelli, Gitto L. Simon's sign: Case report and review of the literature. 2021 Oct 4;90(1):52–6.
16. Fracasso T, Pfeiffer H. Simon's Bleedings in Case of Incomplete Hanging. American Journal of Forensic Medicine & Pathology. 2008 Nov 20;29(4):352–3.
17. Mileva B, Goshev M, Valcheva M, Alexandrov A, Braynova I. Forensic Interpretation and Importance of Simon's Bleeding, Amussat's Sign and Other Typical Findings of Hanging as Diagnostic Signs. Cureus. 2024 Apr 8;
18. Hejna P, Bohnert M. Decapitation in Suicidal Hanging - Vital Reaction Patterns. Journal of Forensic Sciences. 2012 Nov 5;58:S270–7.
19. Clément R, Redpath M, Sauvageau A. Mechanism of Death in Hanging: A Historical Review of the Evolution of Pathophysiological Hypotheses. Journal of Forensic Sciences. 2010 Sep;55(5):1268–71.
20. Tattoli L, Buschmann CT, Tsokos M. Remarkable findings in suicidal hanging. Forensic Science Medicine and Pathology. 2014 Apr 7;10(4):639–42.
21. Tumram NK, Ambade VN, Bardale RV, Dixit PG. Injuries over neck in hanging deaths and its relation with ligature material: Is it vital? Journal of Forensic and Legal Medicine [Internet]. 2014 Feb 1 [cited 2021 Nov 12];22:80–3. Available from: https://www.sciencedirect.com/science/article/abs/pii/S1752928X13003454
22. Anastasova VN, Georgiev AA, Zanzov EI, Velkova KG, Krasteva ES. High-Intensity Focused Ultrasound Thermotherapy for Scar Treatment. PubMed. 2023 Mar 1;36(1):63–7.
23. Georgiev AA, Desislava Tashkova, Lyubomir Chervenkov, Anastasova V, Kitova T. Primary synovial sarcoma of the shoulder: Case report of the "triple sign" on proton density magnetic resonance imaging. Radiology Case Reports. 2022 Dec 26;18(3):943–7