ANIL AGGRAWAL'S
Internet Journal of Forensic Medicine and Toxicology
The world's first online journal devoted entirely to forensic medicine and toxicology · Published 1 January and 1 July

VOL. 27, NO. 1 · JANUARY – JUNE 2026
Downloaded from www.anilaggrawal.com · ISSN 0972-8074 (Online) · https://www.anilaggrawal.com/ij/vol_027_no_001/papers/paper001.html

Posttraumatic Ischemic Brain Stroke After Sharp Neck Injury: A Case Report Based on Autopsy

Ivan Tsranchev[1*], Pavel Timonov[1], Stela Yancheva[1], Kristina Hadzhieva[1], Teodora Gudelova[1], Mirena Sotirova[1], Antoaneta Fasova[1], Elizabet Dzhambazova[1], Petar Uchikov[1]

[1]Medical University of Plovdiv, Republic of Bulgaria, Europe

* Corresponding author: Ivan Tsranchev, Medical University of Plovdiv, Republic of Bulgaria, Europe · tsranchev@inbox.ru

CITE THIS ARTICLE

Tsranchev I, Timonov P, Yancheva S, Hadzhieva K, Gudelova T, Sotirova M, Fasova A, Dzhambazova E, Uchikov P. Posttraumatic Ischemic Brain Stroke After Sharp Neck Injury: A Case Report Based on Autopsy. *Anil Aggrawal's Internet Journal of Forensic Medicine and Toxicology* [serial online], 2026; Vol. 27, No. 1 (January – June 2026): [about 11 p]. DOI: 10.5281/zenodo.15743623. Available from: https://www.anilaggrawal.com/ij/vol_027_no_001/papers/paper001.html

ABSTRACT

Neck injuries are often medical emergencies which require special medical attention. Several complications following neck trauma could be fatal if they are not correctly treated and diagnosed.

The present case is that of a 56-year-old male patient who suffered a sharp-force neck injury and had a surgical reconstruction of the left carotid artery following hospitalisation. Two days after the surgical intervention, the patient went into a state of coma followed by sudden respiratory and cardiac failure, resulting in a lethal outcome. Autopsy and microscopic examination identified the cause for the recent development in the patient's status to be post-traumatic cerebral infarction. The presented case illustrates the importance of closely monitoring patients who suffered neck injuries for serious complications by performing rigorous, detailed examinations, including laboratory, ultrasound, contrast angiography and various specific imaging methods.

Keywords: neck injury, post-traumatic brain stroke, sharp force trauma, fatal outcome, medico-legal case

Introduction

In routine forensic practice, various types of trauma can contribute to neck injuries, potentially leading to severe consequences or even a fatal outcome for the patient. One could directly attribute the lethal outcome to either the initial neck injury or a subsequent complication [1]. One possible complication is a post-traumatic ischaemic brain stroke that can occur after either blunt or sharp

neck injuries, particularly when the neck arteries supplying the brain are involved. Injuries involving the neck arteries can be the cause of blood clot formation in the injured area, which in turn can be a source of emboli in the brain, causing critical cerebrovascular blood flow blockage and death of brain tissue. In emergency cases involving neck injury with damage to the arteries, it's of the utmost importance to identify the severity of the injury as quickly as possible so the patient can be treated with anti-clotting medications to prevent thrombosis and potential stroke formation, thus saving the patient's life.

Case presentation

A 56-year-old male suffered sharp force neck injuries after falling in a bar following excessive alcohol consumption and landing on pieces of broken glass. Immediately after, he was transported by ambulance to the University Hospital "St George", Plovdiv, Bulgaria. After a detailed emergency room assessment, he was transferred to the Department of Vascular Surgery with the diagnosis of an "incised wound in the neck region with severance of the left carotid artery". An emergency reconstruction of the vessel wall was performed. Two days after the surgical intervention, the patient presented with clinical signs of coma and sudden respiratory and cardiac failure, resulting in a lethal outcome. After death, the body was transferred to the Department of Forensic Medicine for routine forensic examination. During the examination, three incised wounds were identified on the anterior surface of the neck. One of the wounds was slit-like, located in the upper third of the frontal surface of the neck. It has undergone surgical treatment and was also stitched with 4 sutures. The length of the wound was 5cm. The edges were relatively clean and smooth; the edges were pointy. The second wound was located on the left half of the anterior surface of the neck and involved the upper, middle, and lower thirds. It was a large zigzag wound, stitched with 15 sutures. The length of the wound was 17 cm. The wound’s edges were also relatively smooth and clean, slightly congested, with marked necrotic areas (Fig. 1). Several additional surgical incisions were located near it. The third injury, another slit-like wound 1 cm in length, was found about 2 cm to the left of the previously described zig-zag wound in the middle third of the neck.



Fig. 1 The zig-zag incised wound on the neck

The skin in the neck area was carefully dissected, and the zigzag wound was examined in depth. The muscles in the left half of the neck were diffusely blood-soaked. The middle third of the sternocleidomastoid muscle had impaired integrity and had undergone surgical suturing. The muscle was dissected to expose and examine the left carotid artery. It was found that a 2.5 cm long section of the common carotid artery underneath the carotid sinus was replaced by an artificial Dacron-type prosthesis. The left common carotid artery was opened during the autopsy. At the upper end of the inserted prosthesis, a reddish-grey dense thrombus was found inside, adhered to the prosthesis-vessel transition (Fig. 2). The thrombus occluded the lumen of the carotid artery by about 90%. At the beginning of the external carotid artery, two transverse tears in its intimal layer were found, measuring 0.2 cm and 0.4 cm. The left jugular vein was also torn at the same level as the described carotid artery prosthesis. The tear measured 0.5 cm and was sutured.

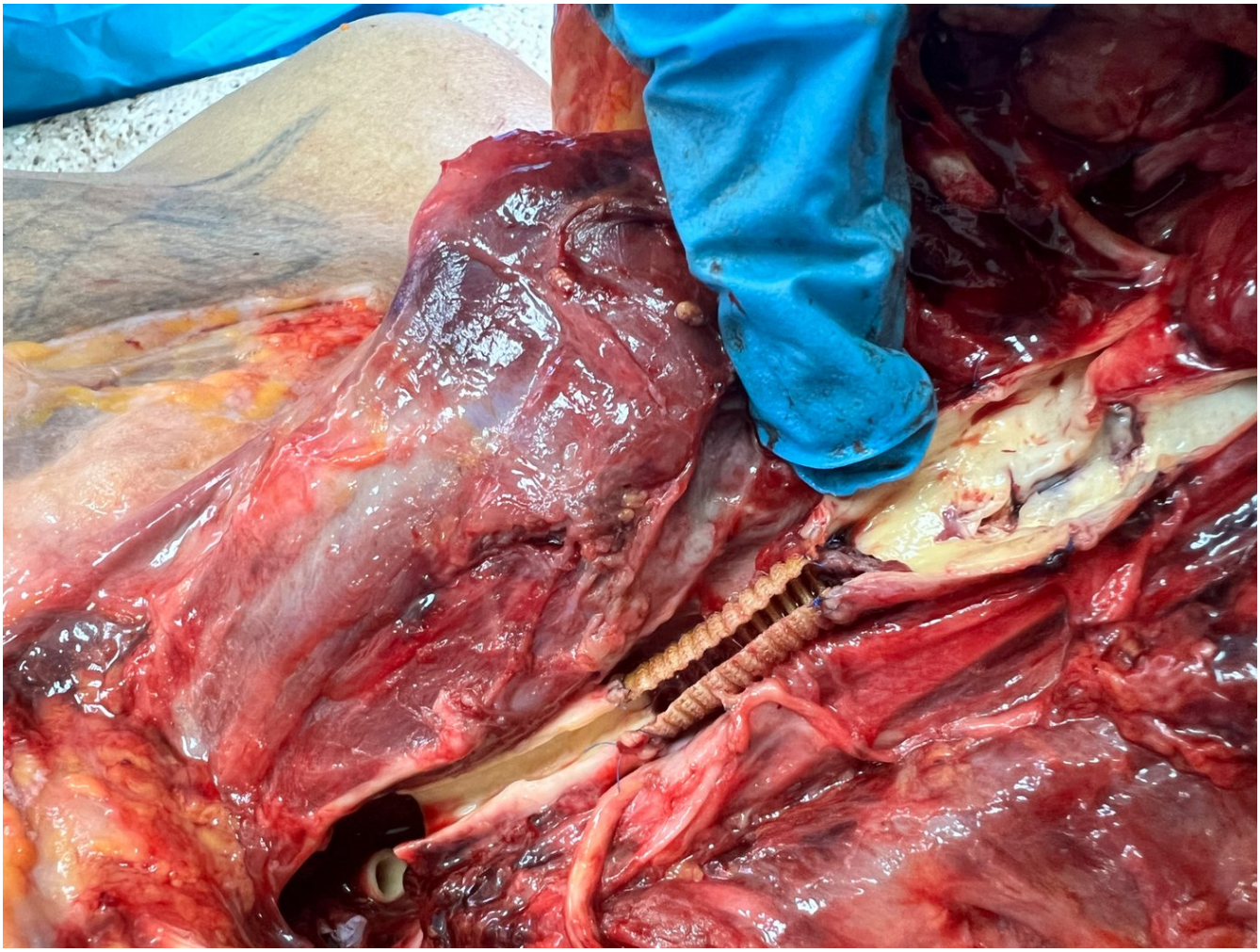

Fig. 2 The left common carotid artery and the inserted prosthesis with the formed thrombus

During the internal examination of the cadaver, all the soft tissues forming the scalp were intact, with a moist surface and a pale pink colour. The bones of the cranium were intact. The dura mater was pearly in colour and had a smooth surface. The cerebral gyri were smoothed, and the sulci were narrowed. In the left parietotemporal region, a section of the cerebral cortex was sunken below the level of the surrounding brain tissue, with a pale greyish-yellowish colour, measuring 4cm by 3.5 cm.

We fixed the brain in a 10% formaldehyde solution for 48 hours before conducting a detailed examination.

The cerebral vessels at the base of the brain were well developed without malformations. A detailed examination revealed a dense, reddish-grey thrombus occluding the left middle cerebral artery.

Consecutive sections of the brain were made. In the left parietotemporal region of the brain, a large area of softening with a livid-greyish colour was found along with reddish haemorrhages around it.

The border between the grey and white brain matter was obliterated (Fig. 3). This area measured approximately 8 cm x 7 cm on the surface of the left cerebral hemisphere, with a depth of 7 cm in the left cerebral hemisphere. The left middle cerebral ventricle was narrowed, and the left cingulate gyrus (gyrus cinguli) was displaced to the right.

In the left half of the hypothalamus, a dark reddish round haemorrhage measuring 0.5 cm x 0.5 cm was found. A similar haemorrhage was also found in the basal nuclei of the left hemisphere, measuring 1 cm x 0.5 cm. Throughout the brainstem (pons and medulla oblongata), numerous dark reddish haemorrhages measuring from punctate to 0.5 cm in diameter were found. In cross-section, the cerebellum was clear and normally developed.



Fig. 3 Infarction in the left cerebral hemisphere

Samples from brain matter were taken, and further microscopic examination was performed with H-E staining under a Primo Star Zeiss microscope with enlargements of 10x, 40x, and 100x. The detailed microscopic examination showed haemorrhages, oedema and multiple massive punctate haemorrhages in the left frontal cortex with multiple massive punctate haemorrhages in the left parietal cortex (Fig. 4), in combination with hyperaemia of blood vessels in the arachnoid layer.

Additional microscopic findings were identified as follows: corpus callosum – mild oedema, hypothalamus – massive punctate haemorrhages and mild oedema, pons – areas with haemorrhages and severe oedema, medulla oblongata – severe oedema, cerebellum – oedema, cortex – mild oedema. Carotid artery vessel wall – part of a vessel with mixed thrombus (Fig. 5). Other samples from internal organs showed no significant pathologic changes.

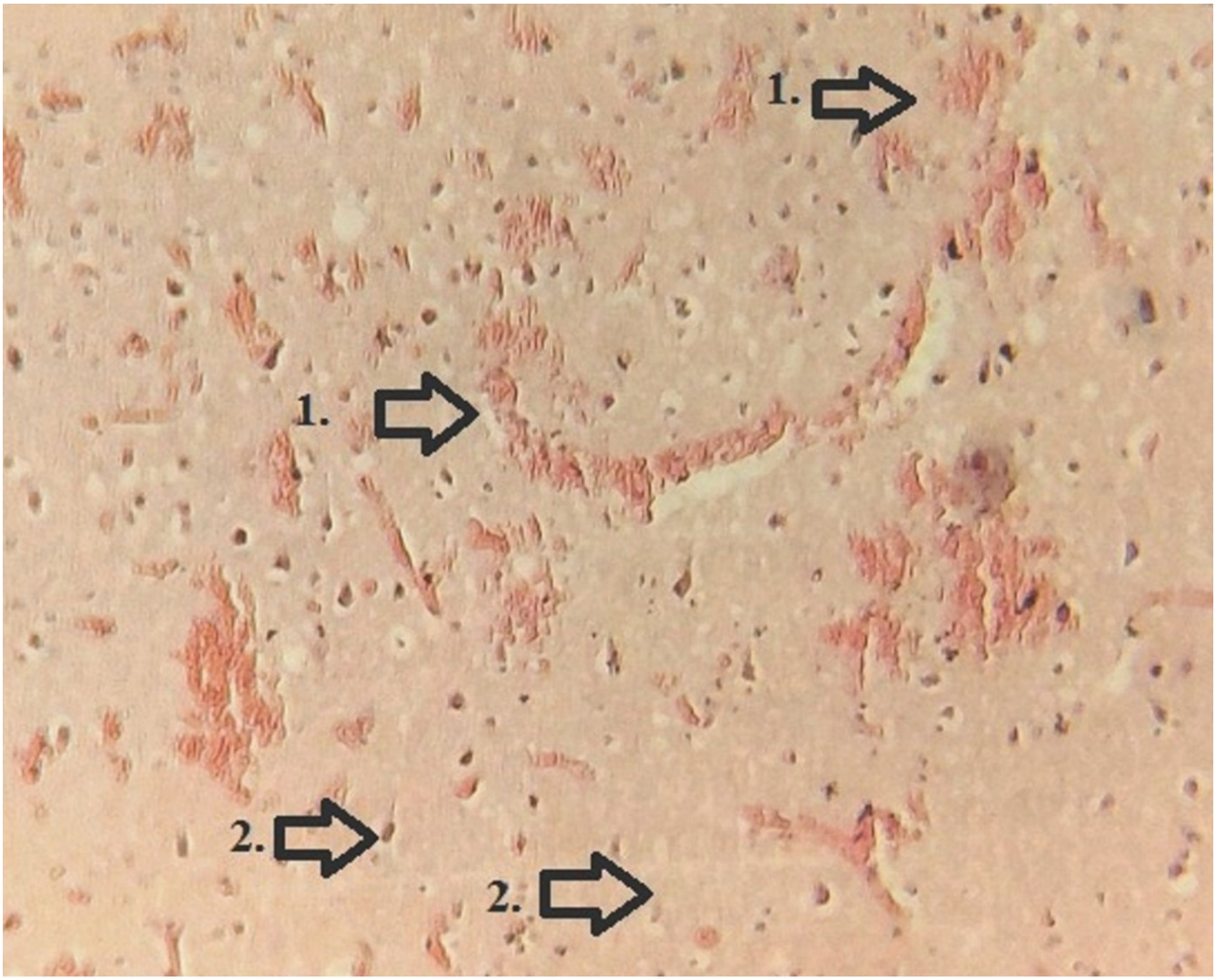

Fig. 4 Multiple haemorrhages and oedema in the left frontal and parietal cortex. H-E staining

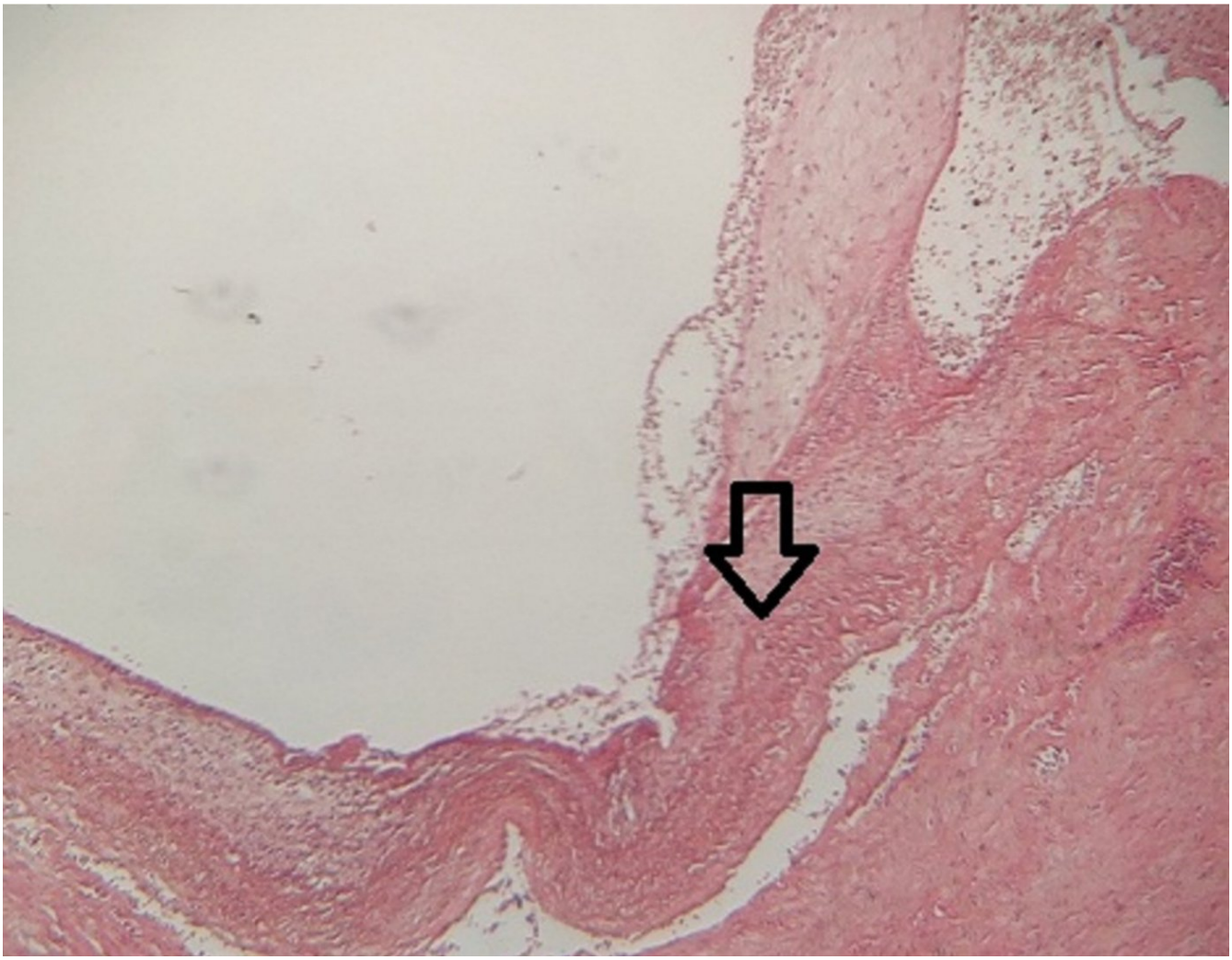

Fig. 5 Carotid artery wall – part of the vessel with mixed thrombus. H-E staining

Discussion

Ischaemic strokes resulting from carotid artery thrombosis following open and closed head and neck trauma have been recognised with increasing frequency recently, and these cases involve not only adults but even children [2-6]. They can lead to life-threatening consequences or even a fatal outcome if they are not diagnosed correctly [7-10]. Ischaemic strokes resulting from carotid artery thrombosis are observed in both blunt and sharp injuries, such as in the case report described above.

Carotid artery thrombosis is a rare but potentially devastating complication that can follow even reconstructive surgery for any major blood vessel in the neck region [11, 12].

In such cases, the non-traumatic genesis of carotid artery thrombosis should also be considered, as it can also result in ischaemic stroke. The most common cause of non-traumatic carotid artery thrombosis is atherosclerosis [13]. In the presence of an unstable atherosclerotic plaque or an ulcerated atherosclerotic plaque, the endothelium of the arteries is compromised. In these cases, coagulation factors are activated, which predisposes to the formation of thrombi. In our case report, during the autopsy, no atherosclerosis of the carotid arteries was detected. Other factors of non-traumatic nature also predispose to the formation of thrombi in the body, such as obesity, pregnancy, smoking, arterial hypertension, and hyperlipidaemia. In our case, the patient had no

previous history of any pre-existing conditions, and none were found during the autopsy. Another cause for ischaemic stroke is emboli. The most common sources of emboli are thrombi formed in a post-infarction aneurysm of the heart, the left auricle of the heart in patients with ventricular fibrillation, and bacterial endocarditis. No such conditions were found in our case. Taking certain medications, such as oral contraceptives, can cause blood clot formation as well.

Different mechanisms can cause traumatic carotid artery thrombosis, including direct traumatic force delivered to the neck, the head, or the oral cavity, resulting in trauma to the soft tissues or even to the cranial bones. Other possible mechanisms are whiplash trauma, seatbelt trauma, or even procedures in the neck region [14].

Studies have indicated that factors significantly increasing the risk of developing carotid thrombosis due to carotid artery injuries include non-penetrating head injury, basilar fractures of the skull, facial fractures, cervical spinal fractures and thoracic injuries [15], with the non-penetrating head injury being the most common single associated injury. In the literature, it is suggested that combined injuries to the upper part of the body/head and neck injuries, especially skull and spinal fractures, and combined injuries to the head and chest increase the risk of damage to the carotid arteries. In our case, the patient did not sustain any other trauma, except for the one on the neck.

In this case, we concluded that the death was caused by an ischaemic brain stroke caused by vascular injury resulting from sharp force trauma to the neck. The patient underwent a reconstructive surgery of the injured section of the common carotid artery, which was replaced with an artificial Dacron-type prosthesis, and suffered a severe complication, despite additional anticoagulation therapy.

During the autopsy, a thrombus was found adhered to the prosthesis-vessel transition. The macroscopic and histopathological examinations determined ischaemic brain stroke. These results prove that the carotid artery damage is where the thrombus was originally formed. Therefore, it is very likely that the thrombus formed due to an intimal tear in the carotid artery caused by the sharp force trauma. The patient died three days later, with clinical signs of coma and sudden respiratory and cardiac failure.

In summary, it is crucial to monitor patients who are hospitalised for treatment for neck trauma caused by a sharp object, especially during the initial days, to detect the emergence of neurological symptoms [16]. It is known that in the early stages of the development of an ischaemic stroke in the brain, changes may not be visualised with standard imaging techniques, such as a CT scan.

Therefore, numerous tests have been developed that can provide an early evaluation of a neurological condition, such as the MMSE (mini-mental state examination), the Folstein test, and the Hodkinson abbreviated mental test score. Highly sensitive imaging methods have also been developed, such as diffusion-weighted magnetic resonance imaging (DWI or DW-MRI), which is highly sensitive to the changes occurring in the lesion and reveals subclinical neurological changes. These imaging-specific methods could be used along with specific biochemical markers, proving the diagnosis [17]. CT angiography is also a highly sensitive and informative imaging method that could help make an accurate diagnosis.

Conclusion

Different diagnostic methods, clinical assessment tests, and biochemical markers could be used in cases of sharp-force neck trauma to diagnose this type of life-threatening post-traumatic complication in trauma patients. In each case of sharp or blunt neck trauma, the diagnosis “post-traumatic ischaemic brain stroke” must be ruled out as a possible serious complication. A detailed examination, including laboratory, ultrasound, contrast angiography, and various specific imaging methods, along with the patient’s rich history, periodic neurologic consultation, and physical examination, must be performed as a standard algorithm for medical action in such clinical cases. That could prevent fatal complications and save a patient’s life.

References

1. Tawil I, Stein DM, Mirvis SE, Scalea TM. Posttraumatic cerebral infarction: incidence, outcome, and risk factors. J Trauma. 2008 Apr;64(4):849-53. Doi: 10.1097/TA.0b013e318160c08a. PMID: 18404047
2. Yılmaz S, Pekdemir M, Sarısoy HT, Yaka E. Post-traumatic cerebral infarction: a rare complication in a pediatric patient after mild head injury. Ulus Travma Acil Cerrahi Derg. 2011 Mar;17(2):186-8. PMID: 21644101.
3. Chaturvedi S, Sohrab S, Tselis A. Carotid stent thrombosis: report of 2 fatal cases. Stroke. 2001 Nov; 32(11):2700-2. PMID: 11692038.
4. Moulakakis KG, Kakisis J, Tsivgoulis G, Zymvragoudakis V, Spiliopoulos S, Lazaris A, Sfyroeras GS, Mylonas SN, Vasdekis SN, Geroulakos G, Brountzos EN. Acute Early Carotid Stent Thrombosis: A Case Series. Ann Vasc Surg. 2017 Nov;45:69-78. doi: 10.1016/j.avsg.2017.04.039. Epub 2017 May 5. PMID: 2848362
5. Caldwell HW, Hadden FC. Carotid artery thrombosis; report of eight cases due to trauma. Ann Intern Med. 1948 Jun;28(6):1132-42. doi: 10.7326/0003-4819-28-6-1132. PMID: 18864120
6. Hockaday TD. Traumatic thrombosis of the internal carotid artery. J Neurol Neurosurg Psychiatry. 1959 Aug;22(3):229-31. doi: 10.1136/jnnp.22.3.229. PMID: 14402209; PMCID: PMC497379
7. Schneider RC, Lemmen LJ. Traumatic internal carotid artery thrombosis secondary to nonpenetrating injuries to the neck; a problem in the differential diagnosis of craniocerebral trauma. J Neurosurg. 1952 Sep; 9(5): 495-507. doi: 10.3171/jns.1952.9.5.0495. PMID: 12981571.
8. Moulakakis KG, Mylonas SN, Lazaris A, Tsivgoulis G, Kakisis J, Sfyroeras GS, Antonopoulos CN, Brountzos EN, Vasdekis SN. Acute Carotid Stent Thrombosis: A Comprehensive Review. Vasc Endovascular Surg. 2016 Oct;50(7):511-521. doi: 10.1177/1538574416665986. Epub 2016 Sep 19. PMID: 27645027
9. Julia C. Schmidt, Dih-Dih Huang, Andrew M. Fleming, Valerie Brockman, Elizabeth A. Hennessy, Louis J. Magnotti, Thomas Schroeppel, Kim McFann, Landon D. Hamilton, Julie A. Dunn, Missed blunt cerebrovascular injuries using current screening criteria — The time for liberalised screening is now. Injury, Volume 54, Issue 5, 2023, Pages 1342-1348, ISSN 0020-1383, https://doi.org/10.1016/j.injury.2023.02.019
10. Macdonald S. Brain injury secondary to carotid intervention. J Endovasc Ther. 2007 Apr;14(2): 219-31. doi: 10.1177/152660280701400215. PMID: 17488181.
11. Setacci C, de Donato G, Setacci F, Chisci E, Cappelli A, Pieraccini M, Castriota F, Cremonesi A. Surgical management of acute carotid thrombosis after carotid stenting: a report of three cases. J Vasc Surg. 2005 Nov; 42(5):993-6. doi: 10.1016/j.jvs.2005.06.031. PMID: 16275459.

12. Iancu A, Grosz C, Lazar A. Acute carotid stent thrombosis: review of the literature and long-term follow-up. Cardiovasc Revasc Med. 2010 Apr-Jun; 11(2):110-3. doi: 10.1016/j.carrev.2009.02.008. PMID: 20347802.]
13. Torvik A, Svindland A, Lindboe CF. Pathogenesis of carotid thrombosis. Stroke. 1989 Nov; 20(11): 1477-83. Doi: 10.1161/01.str.20.11.1477. PMID: 2815181.
14. Karnecki K, Jankowski Z, Kaliszan M. Direct penetrating and indirect neck trauma as a cause of internal carotid artery thrombosis and secondary ischaemic stroke. J Thromb Thrombolysis. 2014 Oct; 38(3): 409-15. doi: 10.1007/s11239-014-1077-2. PMID: 24748050; PMCID: PMC4143597.
15. Hayakawa A, Sano R, Takahashi Y, Fukuda H, Okawa T, Kubo R, Takei H, Komatsu T, Tokue H, Sawada Y, Oshima K, Horioka K, Kominato Y. Post-traumatic cerebral infarction caused by thrombus in the middle cerebral artery. J Forensic Leg Med. 2023 Jan; 93:102474. doi: 10.1016/j.jflm. 2022.102474. Epub 2022 Dec 24. PMID: 36577210
16. Fisher M, Paganini-Hill A, Martin A, Cosgrove M, Toole JF, Barnett HJ, Norris J. Carotid plaque pathology: thrombosis, ulceration, and stroke pathogenesis. Stroke. 2005 Feb;36(2):253-7. doi: 10.1161/01.STR.0000152336.71224.21. Epub 2005 Jan 13. Erratum in: Stroke. 2005 Oct; 36(10): 2330.
17. Capoccia L, Speziale F, Gazzetti M, Mariani P, Rizzo A, Mansour W, Sbarigia E, Fiorani P. Comparative study on carotid revascularisation (endarterectomy vs stenting) using markers of cellular brain injury, neuropsychometric tests, and diffusion-weighted magnetic resonance imaging. J Vasc Surg. 2010 Mar; 51(3):584-91, 591.e1-3; discussion 592. doi: 10.1016/j.jvs.2009.10.079. Epub 2010 Jan 4. PMID: 20045614