ANIL AGGRAWAL'S
Internet Journal of Forensic Medicine and Toxicology
The world's first online journal devoted entirely to forensic medicine and toxicology · Published 1 January and 1 July

VOL. 27, NO. 2 · JULY – DECEMBER 2026
Downloaded from www.anilaggrawal.com · ISSN 0972-8074 (Online) · https://www.anilaggrawal.com/ij/vol_027_no_002/papers/paper001.html

Domestic Violence Leading to Pediatric Burns: A Clinical Forensic Case From East Java, Indonesia

Ibnu Chaldun[1*], Ahmad Yudianto[2], Putu Bagus Dharma Permana[3]

[1]Forensic Medicine and Medicolegal Specialist Program, Faculty of Medicine, Universitas Airlangga, Surabaya, Indonesia

[2]Postgraduate Forensic Science Study Program, Faculty of Medicine, Universitas Airlangga, Surabaya, Indonesia

[3]Faculty of Medicine, Universitas Airlangga, Surabaya, Indonesia

* Corresponding author: Ibnu Chaldun, Faculty of Medicine, Universitas Airlangga, Surabaya, Indonesia · ibnu.chaldun-2022@fk.unair.ac.id

CITE THIS ARTICLE

Chaldun I, Yudianto A, Permana PBD. Domestic Violence Leading to Pediatric Burns: A Clinical Forensic Case From East Java, Indonesia. *Anil Aggrawal's Internet Journal of Forensic Medicine and Toxicology* [serial online], 2026; Vol. 27, No. 2 (July – December 2026): [about 11 p]. DOI: 10.5281/zenodo.15743408. Available from: https://www.anilaggrawal.com/ij/vol_027_no_002/papers/paper001.html

ABSTRACT

Background

Burns encompassed all types of injuries to the skin and underlying tissues caused by heat, cold (e.g., frostbite), chemicals, electricity, radiation, or trauma. They often result in significant physical, psychological, and legal implications, especially in determining the extent of injury and potential criminal liability. In East Java, Indonesia—a region with a dense population and varied socio-economic conditions—burn cases require meticulous clinical forensic examinations to support law enforcement and legal processes.

Method

This study presents a clinical forensic examination conducted at the request of law enforcement through a visum et repertum letter (No. VER/B/92/IV/YAN.2.14/2023/SPKT Polsek Lakarsantri). The case involved a 17-year-old male patient treated at Dr. Soetomo General Academic Hospital in Surabaya, Indonesia.

Result

The patient sustained burns covering 68% of his total body surface area, involving the face, neck, chest, upper limbs, and lower limbs, accompanied by inhalation trauma. The burns occurred during a fire at his stepfather's house while he was asleep. Clinical management included debridement and wound dressing to prevent infection, reduce exudate, and maintain a moist environment for healing. The forensic evaluation concluded that the injuries could be classified as fatal based on Article 90 of the Indonesian Penal Code.

Conclusion

Comprehensive clinical forensic examinations are vital in burn cases, as the findings are essential for assessing the severity of injuries and determining legal accountability. This case highlights the critical role of forensic evaluations in supporting justice and ensuring appropriate care for burn victims in East Java.

Keywords: forensic sciences; burns; visum et repertum; east java; burn injury severity

Introduction

Burns are thermal injuries with a wide range of clinical consequences, including minor injuries and death. From a medicolegal standpoint, numerous factors must be taken into account when assessing both fatal and non-fatal burn injuries.[1] Burn injuries are a significant global health concern, accounting for approximately 180,000 deaths annually, with nearly two-thirds occurring in low- and middle-income regions such as Africa and Southeast Asia, according to WHO statistics.[2] The Indonesian Ministry of Health's survey data revealed a 35% increase in burn cases from 2014 to 2018, with 1,701 cases (20.19%) reported in 2018, compared to 1,570 cases (18.64%) in 2017, 1,432 cases (17.03%) in 2016, 1,387 cases (16.46%) in 2015, and 1,209 cases (14.35%) in 2014.3 East Java, a province in Indonesia, accounted for 1.66% of burn cases out of 964 total samples, highlighting the regional prevalence of burn injuries in this region.[3]

Traumatic burns requiring legal intervention may result from various circumstances, including household accidents, workplace incidents, negligence, or cases of abuse involving children or parents. The patient's history collected during the clinical evaluation is vital in identifying potential abuse. Inconsistent or illogical explanations for burns, unexplained injuries, or delayed symptoms should raise suspicions of maltreatment. Additionally, the type, pattern, and location of burns are critical factors to assess during the physical examination to establish a connection with possible abuse.[1]

Case Report

On April 14, 2023, at approximately 11:30 PM, the patient, a 17-year-old male, was transported by the Indonesian Red Cross Society "*Palang Merah Indonesia*" (PMI) team to the Emergency Room of Dr. Soetomo General Academic Hospital in Surabaya, following a traumatic incident in which he sustained extensive burns. The local law enforcement of Lakarsantri Police Sector, Surabaya formally submitted a request for a clinical forensic examination of the victim through an official *visum et repertum* request letter (No. VER/B/92/IV/YAN.2.14/2023/SPKT Polsek Lakarsantri). The accompanying documentation specified that the burn injuries sustained by the victim were

allegedly inflicted by the stepfather, who set the victim on fire while the latter was asleep. Upon arrival at the hospital, the patient was fully alert and responsive to the situation.

General Examination

The subject of the clinical forensic evaluation was a 17-year-old male, measuring 165 cm in height, weighing 60 kg, with dark skin, and in a state of good nutritional health. Upon examination, the patient was conscious and oriented despite the evident burn injuries sustained. Vital signs recorded were as follows: blood pressure of 107/77 mmHg, pulse rate of 88 beats per minute, and respiratory rate of 20 breaths per minute. Examination of the chest revealed symmetrical movements without retractions, vesicular breath sounds, and the absence of adventitious sounds such as rhonchi or wheezing. Cardiac auscultation was unremarkable, with no abnormal heart sounds detected. The abdomen was soft, non-tender, with normal bowel sounds. Capillary refill time in the extremities was less than 2 seconds, indicating adequate peripheral perfusion.

Wound Examination

In this case, wounds of varied degrees and depths were observed on each affected body area. Second-degree burns (2a / *mid dermal - deep dermal*) affected 6% of the face and neck (Figure 1). The skin was a reddish-brown color, with the epidermis flaking off in parts. There were also blisters with clear fluid within them. They burned the nose and scorched some of the front hair. They discovered second-degree burns (2a / *mid dermal - deep dermal*) covering 15% of the chest and belly, as well as a reddish-brown color, epidermis peeling on some regions of the skin, and clear fluid-filled blisters. They discovered second-degree burns (2a / *mid dermal - deep dermal*) covering 11% of the back, along with a reddish-brown tint, epidermis peeling on some portions of the skin, and blisters filled with clear fluid. A second-degree burn (2a / *mid dermal - deep dermal*) covering 9% of the area was discovered on the right upper limb, encircling the entire upper side from the upper arm to the fingertips, with a reddish-brown color and epidermis peeling on some parts of the skin, as well as blisters containing clear fluid. A second-degree burn (2a / *mid dermal - deep dermal*) covering 9% of the area was also discovered on the left upper limb, encircling the entire upper side from the upper arm to the fingertips, with a reddish-brown color, epidermal peeling, and blisters containing clear fluid. On the right lower limb, from the knee to the tips of the toes, there was a 1st to 2nd degree burn covering 9% of the area and ranging from *the epidermal to the mid-dermal*. The skin was peeling off in some places, and there were blisters with clear fluid inside them. The left lower limb had a 1st to 2nd degree burn, covering 9% of the area and extending from the skin's surface to the middle layer. The burn was reddish-brown, and blisters were filled with clear fluid. It did not cover the limb from the knee to the toe tips.


RM 13001495


RM 13001495


RM 13001495



Figure 1. Patient external wound examination photographs taken from the right side (top image), face upfront (middle left), front torso (bottom left), right upper extremity (middle center), left upper extremity (bottom center), right lower extremity (middle right), and left lower extremity (lower right).

Supporting Examination

A comprehensive blood test was conducted, revealing a significant increase in white blood cell (leukocyte) count, with a rise of 21,380 g/dL. Blood chemistry tests, including serum albumin, blood urea nitrogen (BUN), serum creatinine, and electrolyte levels, yielded the following results: serum albumin at 3.97 g/dL, serum BUN at 14.2 mg/dL, serum creatinine at 1.1 mg/dL, and electrolytes at 134 Na, 3.8 K, and 103 Cl/L. These clinical chemistry results remain within normal reference ranges. The patient was subsequently referred to a pulmonologist for evaluation of inhalation trauma, which was diagnosed as Ocular Dextra Sinistra (ODS) thermal injury. A chest X-ray was performed, which revealed no abnormalities.

Management

The patient received treatment from a plastic surgeon for his burn injuries. An internal medicine specialist was also consulted, and an insertion of a nasogastric tube (NGT) was performed. The patient was kept on a fasting regimen for the first 24 hours, after which modified Parkland fluid resuscitation therapy was initiated, accompanied by fluid balancing and the insertion of a urinary catheter. Additionally, the patient was referred to an anesthesiologist for the implantation of an endotracheal tube (ETT) and administration of oxygen therapy. A pulmonologist was consulted for inhalation trauma, resulting in the administration of high-dose antibiotics, a chest/thorax examination, and nebulization therapy. Lastly, the patient was referred to an ophthalmologist, who diagnosed corneal and conjunctival sac burns, and prescribed antibiotic eye drops and eye ointment for treatment.

Discussion

Trauma and accidents are typical in forensic cases. Wounds, bleeding, and/or scarring, as well as organ function impairment, are the results of trauma or accidents. Mechanical forces, temperature action, chemical agents, electromagnetic agents, hypoxia, and embolic trauma are among the various types of agents that cause trauma.[4] Trauma patients are classified as minor or major based on a set of medical triage criteria. As a result, in forensics, medical practitioners must describe trauma in a way that is suitable and understandable to the judicial system, as well as indicate its etiology.[5] The patient in this case was burned by a thermal agent at a high temperature (hyperthermia). Flames or hot solid or liquid substances can cause hyperthermia, often known as high temperature. Burns are caused by the impact of heat on skin or body parts that come into contact.[4]

Burns are traumatic injuries that are typically produced by thermal events, although they can also be caused by chemical, electrical, or radiation exposure to the skin, mucous membranes, and deep tissues. The injured area has increased capillary permeability, which allows fluids and big molecules such as albumin to escape out of circulation. This results in considerable fluid loss, particularly if the burns cover a vast surface area, impacting metabolism and body cell function. This patient's burns were caused by thermal damage.[6-8] Thermal burns are caused by a heat source raising the skin's temperature, causing tissue cells to die or char. A temperature of at least 44°C is required for the skin to burn. Burns from high temperatures, such as hot metal, boiling liquids, steam, or fire, are the most prevalent cause. Determination of burn wound qualifications in burn cases is based on the assessment of the depth of damaged tissue, the extent of affected tissue, and

injuries accompanying the burn. Burn wound classification based on the depth of tissue damage is divided into first degree, second degree, and third degree burns (Table 1).[9]

Table 1. Burn wound classification based on depth/thickness

Burn Thickness	Description
First Degree (superficial thickness)	Involves only the epidermis. Painful, dry, red, and blanches with pressure. No blisters. Heals without scarring.
Second Degree (partial thickness)	Involve the epidermis and part of the dermis. Superficial partial thickness (2a): Involves epidermis and superficial dermis. Painful, red, blisters form within 24 hours, blanches with pressure. Heals in 1–2 weeks. Deep partial thickness (2b): Extends deeper into dermis. Reduced pain, reduced/absent blanching, higher risk of scarring. Healing takes weeks.
Third Degree (Full thickness)	Involves destruction of epidermis, dermis, and often subcutaneous tissue. Eschar formation, dry and stiff. Sensation absent due to nerve damage. Requires surgical intervention (e.g., grafting).

The classification of burn severity is divided into three based on the cause, depth, and surface area of the burn as seen from the percentage of TBSA, namely minor, moderate, and major burns (Table 2). The patient had varying degrees and depths of burns on each affected body part. On the face and neck, there are 2nd-degree burns/2a covering 3% and 2nd-degree burns/2b covering 3%.

On the chest and abdomen, there are 2nd-degree burns/2a covering 7.5% and 2nd-degree burns/2b covering 7.5%. On the back, there are 2nd-degree burns/2a covering 5.5% and 2nd-degree burns/2b covering 5.5%. On the right upper limb, there are 2nd-degree burns/2a covering 4.5% and 2nd-degree burns/2b covering 4.5%. On the left upper limb, there are 2nd-degree burns/2a covering 4.5% and 2nd-degree burns/2b covering 4.5%. On the right lower limb, there are 1st-degree burns covering 4.5% and 2nd-degree burns/2a covering 4.5%. On the left lower limb, there are 1st-degree burns covering 4.5% and 2nd-degree burns/2a covering 4.5%. In 1st-degree burns, only the epidermis layer of the skin is affected. In 2nd-degree burns, the epidermis and part of the dermis layer of the skin are affected, which is then classified as superficial dermis. In contrast, a second-degree burn extends into the *deep dermis*.[9]

Table 2. Burn wound classification based on severity.

Criteria	Minor burn	Moderate burn	Major burn
TBSA	<10% in adults, <5% in children or elderly, <2% for full thickness burn	10-20% in adults, 5-10% in children or elderly, 2-5% for full thickness burn	>20% in adults, >10% in children and elderly, >5% for full-thickness burn
Other	N/A	Low-voltage burn, suspected inhalation injury, circumferential burn, concomitant medical problem predisposed to infection (e.g. diabetes, sickle cell disease	High-voltage burn, chemical burn , any clinically significant burn to face, eyes, genitalia or major joints, clinically significant associated injuries (e.g. fracture, other major trauma)

To assess the area of burn wounds accurately and correctly, the use of calculation methods such as the "*Rule of Nines*" is required to produce the total burn area percentage (Figure 2). The Wallace's "*Rule of Nines*" divides the body's surface area into multiples of 9%, except for the perineum, which is estimated to be 1%. [10, 11] However, evidence have shown that this method of estimation is not recommended for use in those younger than 12 years as children exhibit dissimilar body proportions than adults. A more advanced version of burn injury extent estimation is by using the Lund-Browder chart, which was developed by Dr. Charles Lund and Dr. Newton Browder based on their experiences treating burn victims from the 1942 Cocoanut Grove fire. Unlike the Wallace rule of nines, it accounts for age-related variations, adjusting the percentage BSA for the head and legs as children grow, making it particularly effective in managing pediatric burn cases.[12, 13] (click to enlarge)

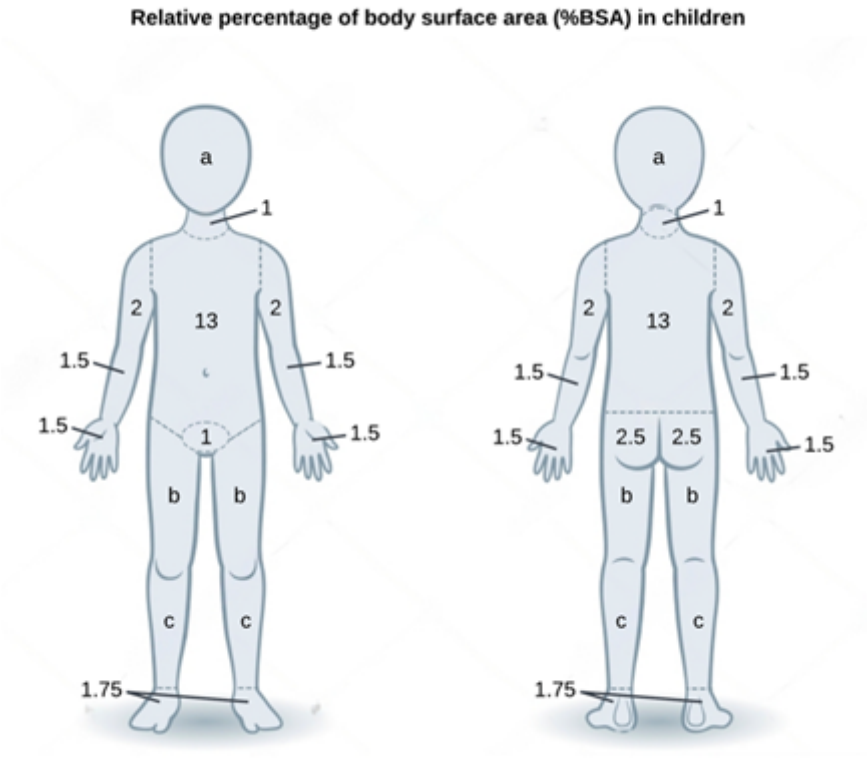

Body Part	Age				
	0 yr	1 yr	5 yr	10 yr	15 yr
a=½ of head	9.5	8.5	6.5	5.5	4.5
b= ½ of thigh	2.75	3.25	4	4.25	4.5
c= ½ of lower leg	2.5	2.5	2.75	3	3.25

Figure 2. Estimation of the total body surface area affected from burn injury based on the Lund and Browder Chart.

Based on the examination of the patient using the Total Body Surface Area (%TBSA) method, the total burn area was calculated to be 68%, involving the face, neck, chest, abdomen, back, both upper limbs, and both lower limbs, caused by exposure to high temperatures (Figure 1). According to the classification of burn severity based on cause, depth, and surface area, this case falls under the category of severe burns, as it exceeds 10% in children (Figure 2).

Table 3. Abbreviated Burn Severity Index.

Parameter	Finding	Points	Parameter	Finding	Points
Sex	Female	1	TBSA (%)	1-10	1
	Male	0		11-20	2
Age	0-20	1		21-30	3
	21-40	2		31-40	4
	41-60	3		41-50	5
	61-80	4		51-60	6
	81-100	5		61-70	7
Inhalation Injury	Yes	1		71-80	8
	No	0		81-90	9
Full-thickness burn	Yes	1		91-100	10
	No	0			

Table 3 (continued)

ABSI	Threat to life	Probability of survival (%)
2-3	Very low	>99%
4-5	Moderate	98%
6-7	Moderately severe	80-90%
8-9	Serious	50-70%
10-11	Severe	20-40%
≥12	Maximum	≤10%

In this case, it is essential to consider the prognosis to predict the patient's mortality. One commonly used method is the Abbreviated Burn Severity Index (ABSI), introduced in 1982 and widely utilized to estimate mortality in burn patients (Table 3).[14-16] The ABSI scoring system involves five variables: gender, age, presence of inhalation trauma, presence of full-thickness burns, and the percentage of TBSA affected. For this patient, the ABSI score was calculated to be 9, indicating a severe prognosis with only a 50–70% probability of survival. The score was determined as follows: gender (male = 0), age (0–20 = 1), inhalation trauma (yes = 1), full-thickness burns (no = 0), and TBSA% (61–70 = 7) (Table 3). Based on the ABSI score, the patient was treated in the intensive care unit to provide the required level of care.

Medico-legal aspects

In this case, the burn injuries are classified under the Indonesian Penal Code (KUHP) Article 90, which pertains to injuries or wounds that cause a fatal danger, and KUHP Articles 353(1) and 353(2), which address premeditated assault resulting in injuries that do not lead to severe harm or death, as well as premeditated assault that causes severe injuries.[17] The examination of burn wounds in a

living person constitutes a form of clinical forensic examination conducted by a forensic doctor, general practitioner, or other medical professionals to assist in the enforcement of law and judicial proceedings, in accordance with the Indonesian Criminal Procedure Code (KUHAP) Articles 120(1) and 133(1) and (2).[17] In this case, the victim is a child, and the perpetrator is the victim's stepfather, making this a case of domestic violence (KDRT), in accordance with the Indonesian Law No. 23 of 2004 on the Elimination of Domestic Violence, specifically Articles 1, 2, 44(1), and 44(2).[18] Additionally, as the victim is a child, this case falls under the scope of Law No. 35 of 2014, which amends Law No. 23 of 2002 on Child Protection, particularly Articles 76C and 80(1), (2), and (3).[19]

Conclusion

The case involves a young male patient with extensive burn injuries covering 68% of his body surface area, compounded by inhalation trauma. From a medicolegal perspective, this case is categorized as an incident resulting in life-threatening injuries, with indications of premeditated abuse causing severe harm. The incident is subject to legal provisions under the Domestic Violence Act and Child Protection Act, emphasizing the need for comprehensive medical, psychological, and legal interventions to ensure justice and holistic care for the patient.

Acknowledgements

The authors acknowledge the use of ChatGPT 4.0, a Generative AI tool developed by OpenAI, during the preparation of this manuscript. Specifically, ChatGPT 4.0 was utilized for translation, grammar checking, and paraphrasing to enhance the clarity and professionalism of the text. This use complies with the Taylor & Francis AI Policy, and the authors confirm that all content generated or revised using ChatGPT 4.0 was reviewed and validated to ensure its accuracy and relevance to the manuscript.

Disclosure

The authors declare no financial or non-financial conflict of interest.

References

1. Aydogdu HI, Kirci GS, Askay M, Bagci G, Peksen TF, Ozer E. Medicolegal evaluation of cases with burn trauma: Accident or physical abuse. Burns. 2021 Jun 1;47(4):888–93.
2. Smolle C, Cambiaso-Daniel J, Forbes AA, Wurzer P, Hundeshagen G, Branski LK, et al. Recent trends in burn epidemiology worldwide: A systematic review. Vol. 43, Burns. Elsevier Ltd; 2017. p. 249–57.
3. Kemenkes RI. Hasil Riset Kesehatan Dasar Tahun 2018. Kementrian Kesehatan RI. 2018;53(9):1689–99.
4. Kara YA. Burn etiology and pathogenesis. Hot Topics in Burn Injuries. 2018;17(1).
5. Yudianto A. Ilmu Kedokteran Forensik. Surabaya: Scopindo Media Pustaka; 2020.
6. Kumar R, Keshamma E, Kumari B, Kumar A, Kumar V, Janjua D, et al. Burn injury management, pathophysiology and its future prospectives. Journal for Research in Applied Sciences and Biotechnology. 2022;1(4):78–89.
7. Kaddoura I, Abu-Sittah G, Ibrahim A, Karamanoukian R, Papazian Njta. Burn injury: review of pathophysiology and therapeutic modalities in major burns. Ann Burns Fire Disasters. 2017;30(2):95.
8. Jeschke MG, Chinkes DL, Finnerty CC, Kulp G, Suman OE, Norbury WB, et al. Pathophysiologic response to severe burn injury. Ann Surg. 2008;248(3):387–401.

9. Warby R, Maani C V. Burn classification. In: StatPearls [Internet]. StatPearls Publishing; 2023.
10. Kemenkes RI (Indonesia Ministry of Health). Pedoman Nasional Pelayanan Kedokteran Tata Laksana Luka Bakar (Indonesian National Treatment Guidelines on Burn Injury). Jakarta: Keputusan Menteri Kesehatan Republik Indonesia; 2019. 1–116 p.
11. ANZBA. Emergency Management of Severe Burns (EMSB): Course Manual. 18th ed. Australian and New Zealand Burn Association; 2016.
12. Carrougher GJ, Pham TN. Burn size estimation: A remarkable history with clinical practice implications. Burns Open [Internet]. 2024;8(2):47–52. Available from: https://www.sciencedirect.com/science/article/pii/S2468912224000014
13. Hussain S, Ferguson C. BET 1: ASSESSING THE SIZE OF BURNS: WHICH METHOD WORKS BEST? Emergency Medicine Journal. 2009;26(9):664–6.
14. Tobiasen J, Hiebert JM, Edlich RF. The abbreviated burn severity index. Ann Emerg Med [Internet]. 1982;11(5):260–2. Available from: https://www.sciencedirect.com/science/article/pii/S0196064482800966
15. Doyle DJ. Abbreviated Burn Severity Index (ABSI). In: Doyle DJ, editor. Computer Programs in Clinical and Laboratory Medicine [Internet]. New York, NY: Springer New York; 1989. p. 101–5. Available from: https://doi.org/10.1007/978-1-4612-3576-7_22
16. Christ A, Staud CJ, Krotka P, Resch A, Neumüller A, Radtke C. Revalidating the prognostic relevance of the Abbreviated Burn Severity Index (ABSI): A twenty-year experience examining the performance of the ABSI score in consideration of progression and advantages of burn treatments from a single center in Vienna. Journal of Plastic, Reconstructive & Aesthetic Surgery [Internet]. 2024;94:160–8. Available from: https://www.sciencedirect.com/science/article/pii/S1748681524002274
17. Pemerintah Pusat RI (Central Government of Indonesia). Undang-undang (UU) Nomor 1 Tahun 2023 tentang Kitab Undang-Undang Hukum Pidana (Penal Code). Jakarta: DPR RI; 2023.
18. Pemerintah Pusat RI (Central Government of Indonesia). Undang-undang (UU) Nomor 23 Tahun 2004 tentang Penghapusan Kekerasan dalam Rumah Tangga (Elimination of Domestic Violence). Jakarta: DPR RI; 2004.
19. Pemerintah Pusat RI (Central Government of Indonesia). Undang-Undang Republik Indonesia Nomor 23 Tahun 2002 Tentang Perlindungan Anak (Child Protection). Jakarta: DPR RI; 2002.

What's New in This paper

What is already known on this topic?

Burn injuries are a global public health problem, especially in low- and middle-income countries, with high morbidity and mortality rates. Pediatric burns resulting from domestic violence are particularly severe and challenging, requiring clinical and forensic evaluation to ensure both medical care and legal justice.

2. What question did this study address?

This study examined how clinical forensic assessment can support legal processes in cases of pediatric burns suspected to result from domestic violence, using a real-life case from East Java, Indonesia. It aimed to highlight the role of visum et repertum in identifying life-threatening injuries and guiding judicial outcomes.

3. What does this study add to our knowledge?

This case report underscores the importance of comprehensive clinical and forensic documentation in suspected child abuse cases involving burns. It provides detailed insights into the severity classification, prognosis estimation (using ABSI), and legal interpretations under Indonesian law. Furthermore, it demonstrates the practical application of forensic medicine in supporting child protection efforts.

Suggestions for further development

Future studies should explore a larger series of burn cases resulting from domestic violence to identify patterns, improve forensic protocols, and inform preventive policies. Interdisciplinary collaboration among healthcare, law enforcement, and social services is also essential for more effective interventions and protection of vulnerable populations.