ANIL AGGRAWAL'S
Internet Journal of Forensic Medicine and Toxicology
The world's first online journal devoted entirely to forensic medicine and toxicology · Published 1 January and 1 July

VOL. 28, NO. 1 · JANUARY – JUNE 2027
Downloaded from www.anilaggrawal.com · ISSN 0972-8074 (Online) · https://www.anilaggrawal.com/ij/vol_028_no_001/papers/paper001.html

Misinterpretation of Radiological Findings: A Case of Corneal Cherry Ingestion Mimicking Body Stuffing

Foroozan Faress[1], Kurosh Jodaki[2], Leyla Abdolkarimi[3], Zeynab Nasri Nasrabadi[4], Sayed Mahdi Marashi[1*]

[1]Department of Forensic Medicine, School of Medicine, Iran University of Medical Sciences, Tehran, Iran
[2]School of Nursing and Midwifery, Shohadaye Haft-e Tir Hospital, Iran University of Medical Sciences, Tehran, Iran
[3]Rajaie Cardiovascular Medical and Research Center, Iran University of Medical Sciences, Tehran, Iran
[4]Department of Pediatrics, School of Medicine, Iran University of Medical Sciences, Tehran, Iran

* Corresponding author: Sayed Mahdi Marashi, Associate Professor of Forensic Medicine and Clinical Toxicology, Shohadaye-Haftom-e-Tir Hospital, Tehran, Iran · marashi.mh@iums.ac.ir

CITE THIS ARTICLE

Faress F, Jodaki K, Abdolkarimi L, Nasri Nasrabadi Z, Marashi SM. Misinterpretation of Radiological Findings: A Case of Corneal Cherry Ingestion Mimicking Body Stuffing. *Anil Aggrawal's Internet Journal of Forensic Medicine and Toxicology* [serial online], 2027; Vol. 28, No. 1 (January – June 2027): []. DOI: 10.5281/zenodo.22386942. Available from: https://www.anilaggrawal.com/ij/vol_028_no_001/papers/paper001.html

ABSTRACT

Body stuffing is the practice of ingesting illicit drugs to evade law enforcement detection, contrasting with body packing, where drugs are encapsulated for safer gastrointestinal passage. Some individuals may be falsely accused of drug smuggling despite having no intent. This case presents a 30-year-old woman suspected of drug trafficking under such circumstances. Initially presenting with abdominal pain and confusion, her urine toxicology revealed methamphetamine and morphine. A CT scan showed oval-shaped dense areas in her colon, raising concerns about drug packets. The patient was monitored and given polyethylene glycol for gastrointestinal decontamination, but experienced no bowel movements in 24 hours. After castor oil was administered, she finally had a bowel movement, yet no drug packets were found. Further questioning revealed she had consumed 500 grams of corneal cherries with intact kernels. This case highlights the challenges in diagnosing body stuffing, the importance of thorough patient history, and the potential for misidentifying non-illicit substances as drugs. It underscores the need for improved training for law enforcement and healthcare professionals to recognize body stuffing signs and avoid unnecessary detention or treatment based on misinterpretation of imaging results. The findings emphasize the importance of careful evaluation and communication between medical

staff and radiologists to enhance patient outcomes and reduce the risks associated with these practices.

Keywords: Drug smuggling, Body stuffing, radiology pitfalls, Gastrointestinal decontamination

Introduction

Body stuffing refers to the practice of ingesting substantial amounts of illicit drugs with the intention of smuggling them or evading law enforcement detection. This contrasts with body packing, where drugs are encapsulated for safer passage through the gastrointestinal tract. Typically unencapsulated substances are involved in body stuffing, which is frequently associated with drug trafficking and carries considerable health risks, complicating management for both law enforcement and healthcare professionals (1, 2).

Patients who engage in body stuffing may present with a range of symptoms, such as abdominal pain, nausea, vomiting, and signs of drug toxicity. A detailed patient history and a thorough physical examination are essential for developing appropriate differential diagnoses (3). Both body stuffers and body packers share the objective of avoiding arrest or successfully smuggling drugs (2). The intense pressure and fear of legal consequences often compel individuals to resort to these dangerous methods (4).

Ingesting large quantities of drugs poses immediate health threats, with overdose representing the most severe consequence (1, 2). Providing law enforcement with training to recognize signs of body stuffing can improve detection and intervention efforts, as there have been reported fatalities among incarcerated individuals (5). It is vital to understand the typical behaviors and associated risks of body stuffing to enhance patient outcomes and healthcare responses. It is important to recognize that there are instances where an individual may be accused of drug smuggling without having any genuine intent to do so. Here, we present the case of a 30-year-old individual, who has been suspected of involvement in drug trafficking.

Case Presentation

A 30-year-old female was brought to the Emergency Department (ED) by emergency medical services following a fall from a height. She was initially suspected of drug possession and use due to her erratic behavior, which included fleeing from law enforcement after entering a café. During the incident, she entered a construction site and jumped from the first floor. Upon admission, she denied any history of illicit drug use but reported epigastric pain, right flank pain, left lower extremity pain, and a headache. She did not exhibit any symptoms such as vomiting, chest pain, cough, shortness of breath, or seizures. Although she was initially cooperative, her level of confusion and drowsiness increased during the physical examination.

Vital signs revealed a blood pressure of 110/70 mmHg, a pulse of 88 beats per minute, a respiratory rate of 19 breaths per minute, a temperature of 37°C, and oxygen saturation at 95% on room air. A 12-lead electrocardiogram was within normal limits. Initial laboratory tests indicated a mild leukocytosis (WBC: 19,900) and hematuria; however, other parameters, including complete blood count, renal function tests (creatinine and blood urea nitrogen), liver function tests, amylase, lipase, and the coagulation profile, were within normal ranges. A computed tomography (CT) scan of the brain was normal, while a CT of the abdomen and pelvis revealed small, oval-shaped dense areas

throughout the colon, especially in the rectal area, with no indications of obstruction or rupture (Figure 1).

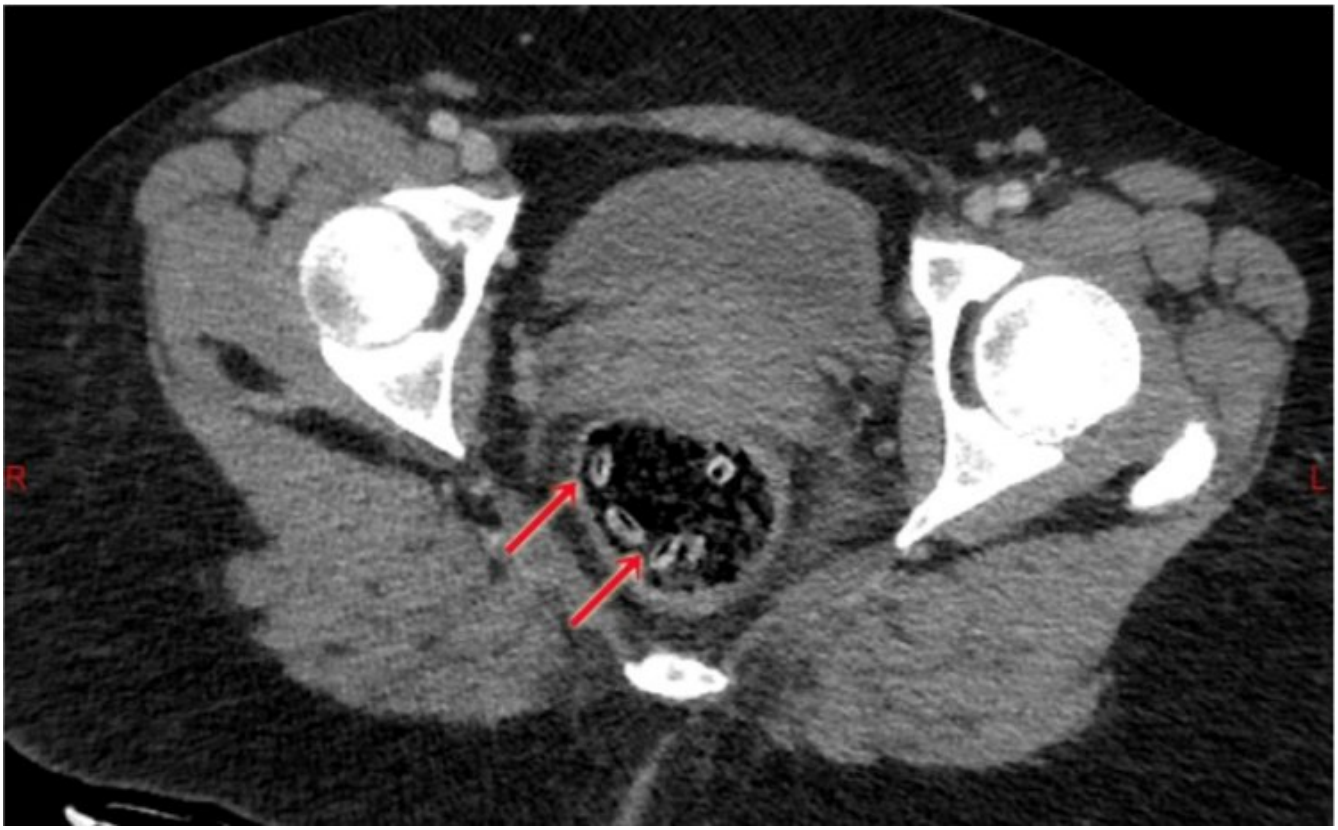

Figure 1. Abdominal-pelvic computed tomography (CT) scan displaying small, oval-shaped high-density areas in the rectal region. Observe the uniform structure of substances suspected to be drug packets (red arrows).

Upon further questioning, the patient continued to deny having ingested any drug packets. A digital rectal examination showed no abnormalities. Urine toxicology confirmed the presence of methamphetamine, amphetamines, morphine, and methadone. The patient was monitored for vital signs, and to facilitate gastrointestinal decontamination, 1000 cc of polyethylene glycol was administered orally over six hours. Afterward, a bisacodyl suppository was prescribed due to a significant lack of bowel movements. Despite these interventions, the patient did not have any bowel movements in the first 24 hours.

On day two, she remained fully conscious without symptoms of depressant or stimulant toxidrome. The patient received 40 mL of castor oil several times over a 24-hour period, which resulted in a bowel movement 48 hours after admission, but no drug packets were found in the stool. A more comprehensive patient history revealed ongoing opioid addiction with recent use of methamphetamine and methadone prior to hospital admission. He reported that he was in the cafe to gamble and ran away due to police presence. Upon further questioning, and after discussing the results of the abdominal imaging and possible life-threatening consequences of the medication, the patient finally disclosed the consumption of approximately 500 grams of corneal cherries with intact kernels. Re-evaluation of his CT scan showed that the small oval densities corresponded to the shape of corneal cherry nuclei. Her statements were relayed to law enforcement, who subsequently announced that the initial suspicions regarding the patient's drug possession had been cleared during the investigation. After three days of hospitalization, the patient was

discharged with the recommendation to follow maintenance treatment with methadone in an outpatient clinic.

Discussion

This case involves a 30-year-old woman who was suspected of body stuffing after fleeing from law enforcement at a café where she was gambling. It highlights several crucial considerations for managing individuals suspected of being body packers or stuffers.

In the concluding phase of the drug trafficking continuum, individuals, including street vendors or users possessing packages of illicit substances, may engage in body stuffing. This practice involves the rapid ingestion of these packages to evade detection by the police in anticipation of a potential search (6, 7). Identifying drug smugglers through medical history and physical examination can be challenging, as some patients may be untruthful due to their fear of arrest (8). Individuals utilizing body packs can ingest up to 1 kilogram of illicit substances, typically divided into 50 to 100 pellets, with each pellet containing 10 to 20 grams of illicit drugs. Additionally, they may take medications to diminish peristalsis and delay the expulsion of pellets during extended travel (7, 9).

Urine drug screening in suspected drug smugglers can be a valuable diagnostic tool, as positive results may support the need for further radiological investigations. In these instances, urine drug testing can assist in identifying the ingested substances (10). However, distinguishing a positive test result from recreational use versus one arising from the release of drugs from an ingested packet presents a challenge. Therefore, the diagnosis and targeted management of body packers primarily depend on radiographic evidence of foreign bodies. The identification of internal drug packets should be conducted using low-dose computed tomography (CT) without contrast. Abdominal CT scans typically reveal the body packets as multiple, oval or round, radiodense foreign bodies distributed throughout the abdominal cavity in a relatively organized manner. The sensitivity of this test exceeds 95% (11). However, detecting body stuffing presents greater challenges. Individuals who engage in body stuffing often utilize unconventional packaging to conceal the drugs, necessitating careful consideration during evaluation. This method carries the risk of packet rupture and unpredictable transit through the gastrointestinal tract, potentially leading to delayed toxicity. Drugs encased in fragile packaging, especially if there is airspace between layers, may possess sufficient density to remain undetected. If the patient consumes large quantities of fluids, this could aid in natural transit, but may also result in the packages being retained in the stomach, complicating the situation (12).

In our case, the CT scan of the abdomen and pelvis revealed small oval-shaped dense areas dispersed throughout the colon, particularly in the rectal region. Given that this is a typical appearance associated with body packing (11), along with the positive urine screening results for methamphetamine, amphetamines, morphine, and methadone, appropriate caution was warranted. Despite the positive results from our patient's urine screening, she did not show any clinical signs of opioid poisoning, such as pinpoint pupils or respiratory depression. Additionally, there were no signs of stimulant poisoning, such as tachycardia or hypertension. However, she did exhibit drowsiness and confusion. As a result, we decided to administer polyethylene glycol and closely monitor the patient. While some researchers advocate for whole bowel irrigation (WBI), it is important to remember that it is contraindicated for unstable or asymptomatic body stuffers. This is because the drug packages are often poorly wrapped, and WBI could increase the risk of rupture

and subsequent drug absorption, particularly due to the elevated volume of fluid in the gastrointestinal lumen (2).

Yamamoto et al. suggest that if the patient is asymptomatic or if the exhibited signs and symptoms have subsided, a monitoring period of 6 hours from the time of admission is deemed sufficient (13). Nevertheless, there are no established official guidelines regarding the appropriate duration of monitoring for body stuffers (12). Consequently, we have opted to closely observe the patient to confirm the successful elimination of ingested substances. Although there were no indications of a depressant or stimulant drug toxidrome in our patient, and symptoms of drowsiness and confusion completely resolved within 24 hours, a bisacodyl suppository was prescribed, and castor oil was administered due to the absence of fecal excretion. It is crucial to emphasize that some researchers oppose the use of mineral oil laxatives for facilitating the elimination of ingested packets. They express concerns regarding this practice, particularly with paraffin oil, the most commonly used laxative, which carries the risk of causing condom-packet rupture and subsequent drug toxicity (11, 14). However, in our patient, the small, oval-shaped dense objects were significantly smaller than the typical drug packaging used by drug smugglers with condoms. Despite the administration of laxatives, the patient did not pass any packages after several bowel movements. Upon further questioning and after discussing the results of the abdominal imaging alongside the potential life-threatening consequences of the situation, the patient revealed that she had consumed approximately 500 grams of corneal cherries with intact kernels. A re-evaluation of the CT scan showed that the small oval densities matched the shape of the corneal cherry nuclei.

This case highlights the potential pitfalls in misidentifying foreign bodies that are not illegal substances, which can mimic the appearance of drug packets. As seen with the corneal cherries, existing literature also notes other swallowed foreign bodies that can mimic drug packets, including various fruits, hardened fecal masses, stones, and grains (12,15).

Our patient had repeatedly claimed that she did not swallow any narcotics with the intention of evading the law or smuggling, but this assertion appeared unreliable based on the evidence from the CT scan, the positive screen test, and her attempt to flee upon seeing the police. It is important to note that body stuffers typically distrust authorities and are usually reluctant to admit to concealing drugs. This mistrust places them at an increased risk of complications. We should strive to avoid false-positive interpretations regarding the internal concealment of illicit substances; as such misidentifications can result in significant clinical and ethical issues. This encompasses the unlawful restriction of an individual's freedom. Additionally, unnecessary detention imposes financial burdens on the healthcare system (9).

This case report highlights the importance of obtaining a detailed history of food intake and sharing relevant information with the radiologist, as this can significantly influence the interpretation of CT scan images in patients suspected of internal drug concealment. In cases where there is a discrepancy between the CT scan results and the patient's clinical condition, it is advisable to reassess the initial interpretation of the images.

Acknowledgement

We thank all the staff of the Intensive Care Unit and Emergency Department of Shohadaye-Haftom-e-Tir Hospital. We also thank the patient for allowing us to present this case in a medical journal for

educational purposes. We employed an artificial intelligence model (GPT-4) to assess the quality of the English language used in this article.

Funding

We did not receive any funding for this work.

Conflict of Interest

The authors have no conflicts of interest to declare.

Authorship: All the authors have fulfilled the authorship criteria as per the International

Committee of Medical Journal Editors (ICMJE).

Contributorship: All authors are responsible for the study conception, design, and supervision on data collection, and finalizing of the manuscript under supervision of the 5th author.

Guarantor: The 5th author is the guarantor for the work.

Ethical Approval

This study is a case report. The patient consented to us presenting her case in a medical journal for educational purposes.

References

1. Booker RJ, Smith JE, Rodger MP. Packers, pushers and stuffers--managing patients with concealed drugs in UK emergency departments: a clinical and medicolegal review. Emerg Med J. 2009;26(5): 316-20. PMID: 19386860 Hassanian-Moghaddam H, Amraei F, Zamani N. Management recommendations for body stuffers at emergency units. Arh Hig Rada Toksikol. 2019;70(2):90-96. PMID: 31246574
2. Jordan MT, Bryant SM, Aks SE, Wahl M. A five-year review of the medical outcome of heroin body stuffers. J Emerg Med. 2009;36(3):250-6. PMID: 18024071
3. Cunningham N. Medicolegal issues surrounding body packers, pushers and stuffers. Emerg Med Australas. 2012;24(6):590-4. PMID: 23216718
4. Norfolk GA. The fatal case of a cocaine body-stuffer and a literature review - towards evidence based management. J Forensic Leg Med. 2007;14(1):49-52. PMID: 16442337
5. Traub SJ, Hoffman RS, Nelson LS. Body packing--the internal concealment of illicit drugs. N Engl J Med. 2003;349(26):2519-26. PMID: 14695412
6. Cappelletti S, Piacentino D, Sani G, Bottoni E, Fiore PA, Aromatario M, Ciallella C. Systematic review of the toxicological and radiological features of body packing. Int J Legal Med. 2016;130(3):693-709. PMID: 26932867
7. Elkbuli A, Ehrhardt JD Jr, Hai S, McKenney M, Boneva D. Surgical care for ingested cocaine packets: Case report and literature review. Int J Surg Case Rep. 2019;55:84-87. PMID: 30716708
8. Jimenez N, Tran NT, Poletti PA, Platon A, Meach F, Juillerat A, Getaz L, Wolff H. Case Report: Don't chew the fufu: a case report of suspected drug body stuffing. F1000Res. 2019;8:1156. PMID: 33633839
9. Gherardi RK, Baud FJ, Leporc P, Marc B, Dupeyron JP, Diamant-Berger O. Detection of drugs in the urine of body-packers. Lancet. 1988;1(8594):1076-8. PMID: 2896912

10. Reginelli A, Russo A, Urraro F, Maresca D, Martiniello C, D'Andrea A, Brunese L, Pinto A. Imaging of body packing: errors and medico-legal issues. Abdom Imaging. 2015;40(7):2127-42. PMID: 26063072
11. Jalbert B, Tran NT, von Düring S, Poletti PA, Fournier I, Hafner C, Dubost C, Gétaz L, Wolff H. Apple, condom, and cocaine - body stuffing in prison: a case report. J Med Case Rep. 2018;12(1):35. PMID: 29427992
12. Yamamoto T, Malavasi E, Archer JR, Dargan PI, Wood DM. Management of body stuffers presenting to the emergency department. Eur J Emerg Med. 2016;23(6):425-429. PMID: 25969343
13. Voeller B, Coulson AH, Bernstein GS, Nakamura RM. Mineral oil lubricants cause rapid deterioration of latex condoms. Contraception. 1989;39(1):95-102. PMID: 2535978
14. Flach PM, Ross SG, Ebert LC, Thali MJ, Ampanozi G. Response to "the detection of internal cocaine drug packs: a radiological challenge in the future?". Eur J Radiol. 2013;82(9):1588-90. PMID: 23726125

What's New in This paper

What is already known about this topic?

Differential diagnoses in the context of body smuggling refer to the various medical conditions and syndromes that may be encountered or mistaken for the act of smuggling individuals within the body or concealment of illegal items within the body. Medical professionals may need to recognize certain markers or signs of body concealment during examinations.

What this study adds?

The presence of uniform substances in CT scan images should prompt us to reconsider the possibility of consuming something other than smuggled substances in a patient who denies it and shows no signs of poisoning.

Suggestions for further development

Considering that there is still no consensus on the duration required for the hospitalization and observation of asymptomatic patients suspected of body smuggling, it is necessary for future studies to be conducted with the aim of evaluating the minimum safe discharge time for suspected patients.