ANIL AGGRAWAL'S
Internet Journal of Forensic Medicine and Toxicology
The world's first online journal devoted entirely to forensic medicine and toxicology · Published 1 January and 1 July

VOL. 28, NO. 2 · JULY – DECEMBER 2027
Downloaded from www.anilaggrawal.com · ISSN 0972-8074 (Online) · https://www.anilaggrawal.com/ij/vol_028_no_002/papers/paper001.html

Vaping-Induced Lung Injury Death In Malaysia: An Autopsy Case Report

Razuin Rahimi[1,2*], Nur Hidayah Shamsuddin[2], Norizal Mohd Noor[3], Farah Lyna Darwin Egyptoman Darwin[2]

[1,2]Department of Forensic Pathology, Faculty of Medicine, Universiti Teknologi MARA, Selangor, Malaysia
[2]Department of Forensic Medicine, Hospital Sungai Buloh, Ministry of Health Malaysia
[3]Department of Pathology, Faculty of Medicine, Universiti Teknologi MARA, Selangor, Malaysia

* Corresponding author: Assoc. Prof. Dr. Razuin Rahimi, Department of Forensic Pathology, Faculty of Medicine, Universiti Teknologi MARA, Sungai Buloh Campus, 47000 Sungai Buloh, Selangor, Malaysia · dr_razuin@uitm.edu.my

CITE THIS ARTICLE

Razuin R, Nur Hidayah S, Norizal MN, Farah Lyna D. Vaping-Induced Lung Injury Death In Malaysia: An Autopsy Case Report. *Anil Aggrawal's Internet Journal of Forensic Medicine and Toxicology* [serial online], 2027; Vol. 28, No. 2 (July – December 2027): [about 11 p]. DOI: 10.5281/zenodo.23219181. Available from: https://www.anilaggrawal.com/ij/vol_028_no_002/papers/paper001.html

ABSTRACT

Introduction

E-cigarette or vaping product-use associated lung injury (EVALI) is a new disease associated with aerosol inhalation from the device primarily aimed to deliver nicotine. Clinical presentations include cough, shortness of breath, fever, and systemic symptoms. **Case report:** We report a case of a 38-year-old gentleman who was brought-in-dead to the Forensic Department and undergone a medico-legal autopsy examination. The deceased was an ex-smoker of fifteen years before switching to e-cigarettes for the past 5 years. He was presented with cough and chest pain for one year which worsened three days prior to his demise. **Results:** Autopsy examination showed peripheral cyanosis, marked pulmonary oedema and vascular congestion. Microscopic examination of the lungs revealed diffuse alveolar injury with inflammation of the airways. The alveoli were generally thickened, and hyaline membrane formation was observed in some areas. Abundant foamy macrophages, lymphocytic and eosinophilic infiltrations were seen within the areas of acute lung injury. Foreign body material was also visible in focal areas via polarized light microscopy. **Conclusions:** We wish to demonstrate the pathophysiological changes of vaping via autopsy and histopathological examination to increase public awareness of the harmful effects of e-cigarette usage.

Keywords: E-cigarette; EVALI; Vaping; Organizing pneumonia; Autopsy

Introduction

Electronic cigarettes (e-cigarettes) were originally developed as an alternative to tobacco smoking and has been popular due to its fashionable devices and addictive contents of the E-liquid.[1] E-cigarettes are battery-powered devices that produce an aerosol that is inhaled into the lungs by heating a liquid. [2,3] The composition of the aerosol is determined by the content of the liquid, of which apart from nicotine, also contains solvent such as vegetable glycerin, propylene glycol and Vitamin E acetate that are mixed with various flavours, other chemicals and metals except tobacco. [3,4] The device is primarily used to deliver various concentrations of nicotine without tobacco smoke, and sometimes, an illicit substance such as tetrahydrocannabinol (THC). [3,5,6] The inhalation of the aerosol is also known as 'vape', due to the perception that the aerosol is water vapour, while it actually consists of fine chemical particles. [5,6]

The first outbreak of lung injury associated with vaping was reported in the United States of America (USA) in August 2019.[7] Typical manifestations include cough, shortness of breath, fever, fatigue, nausea, and diarrhoea.[8] As it quickly caught the attention of the Centre for Disease Control and Prevention (CDC), the centre termed this new disease as E-cigarette or vaping product-use associated lung injury (EVALI).[3] The increase in vaping habit worldwide has also prompted many centres internationally to investigate the pulmonary diseases in relation to vaping such as chemical pneumonitis, acute eosinophilic pneumonia, lipoid pneumonia acute lung injury and organizing pneumonia.[9] While its pathophysiology is quite similar to chemical pneumonitis based on the presence of airway inflammation, oedema and hypoxaemia, it is unclear which particular chemical is damaging to the lungs.[8]

Since the introduction of e-cigarettes in the Malaysian market during the mid-2000s, there have been a few reported probable EVALI cases, although most are likely to be underreported.[10] However, there have been no known reported cases of fatality associated with vaping thus far. In this case report, we wished to demonstrate the histopathology findings associated with vaping, from a medico-legal autopsy case in Selangor, Malaysia.

Case Presentation

A 38-year-old gentleman was found dead in his sleep at home. As he was staying with his family, preliminary history was obtained from the spouse. He experienced respiratory symptoms of bouts of cough and occasional chest pain for one year. Approximately three days prior to his demise, he complained of worsening cough and chest pain, however, he refused to seek medical treatment. Further history revealed that he was a chronic smoker for about fifteen years before switching to e-cigarettes for the past five years. There was no underlying medical illness. The body was brought to the Forensic Department for a medico-legal autopsy.

Autopsy showed an obese adult male, measuring 170 cm in length and 100 kg in weight, with body mass index of 34.6 kg/m^2. There was no injury or congenital deformity seen. Post-mortem changes such as lividity and rigor mortis were present. Bluish discolouration of the fingernail beds was prominent, indicating cyanosis. Internal examination showed intact skull and normal brain anatomy. Examination of the thoracic organs showed normal heart weight (360 gm) with mild hypertrophy of the left ventricular wall. The left anterior descending coronary artery showed an approximately 50% luminal occlusion by atheromatous plaque. Both the right coronary artery and

the left circumflex artery were patent. Both the lungs were within normal weight, as the right lung weighed 395 gm and the left lung weighed 355 gm (Fig. 1A). The tracheal lumen contained whitish froth extending to the main bronchi, in keeping with pulmonary oedema. Cut surfaces of both lungs showed vascular congestion with areas of consolidations (Fig. 1B and C). There was no mucous plug present in the bronchi or its distal branches, and the vasculatures were patent. Enlarged hilar lymph nodes were noted. Examination of the other internal organs such as the liver, spleen, kidneys, and intestines generally showed congestion, with no gross pathology observed.

Several postmortem specimens were obtained for laboratory investigations. Forensic toxicology analysis showed negative results for alcohol and common drugs, from both the blood and urine samples. Rapid test antigen and Polymerase Chain Reaction (PCR) for SARS-CoV-2 (COVID-19) were negative. Other infectious disease screening also showed negative result for Human Immunodeficiency Virus (HIV), Hepatitis B and C. Lung tissue specimens were also sent for microbiology study, the tissue culture yielded growth for *Klebsiella pneumoniae, Streptococcus agalactiae* and *Streptococcus oralis*

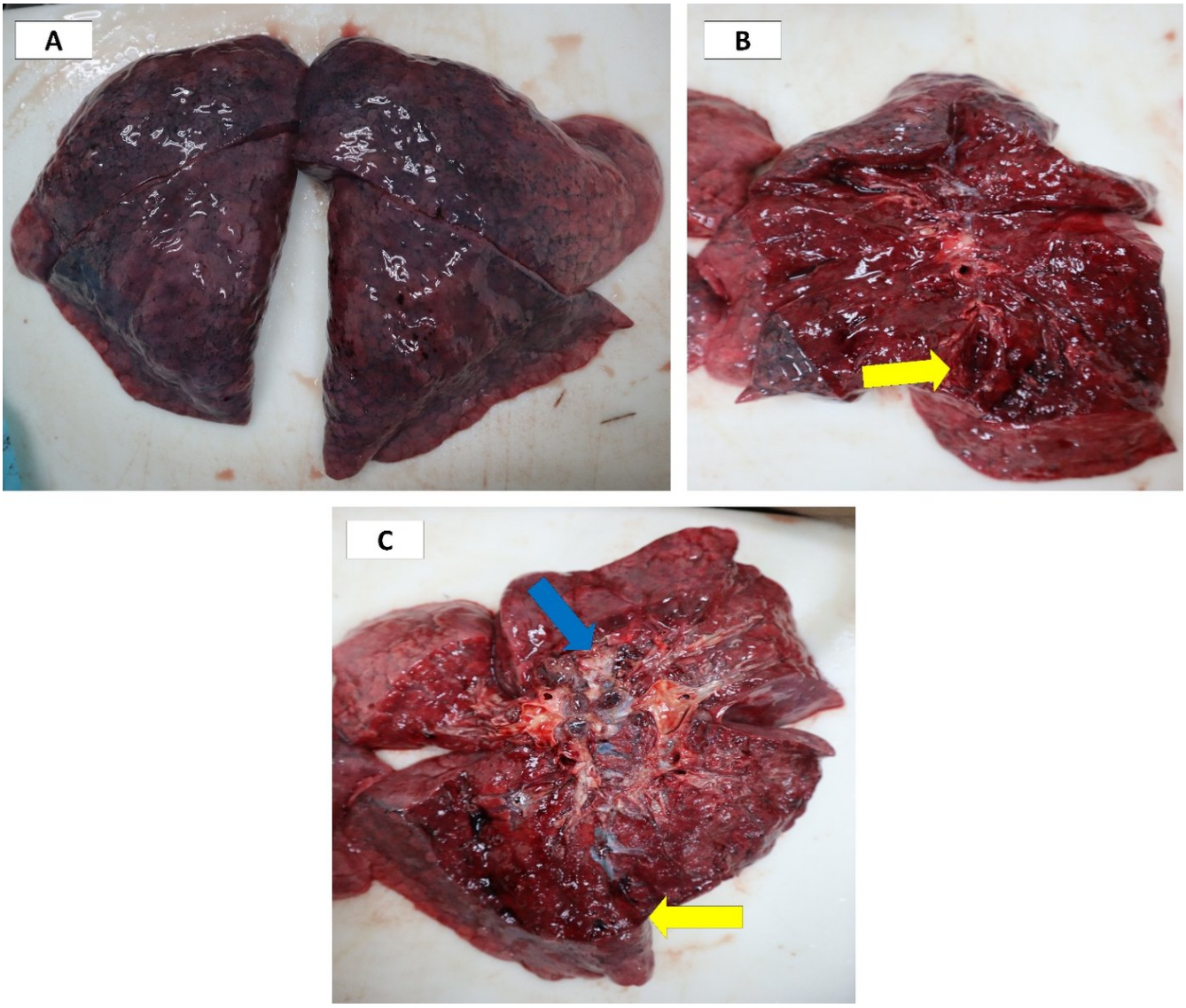

Fig. 1 A The right and left lungs showing dark red pleural surface. B Cut surface of the right lung showing patchy consolidations and haemorrhages at the lower segment of the lung field (yellow arrow). C Cut surface of the left lung also showing area of consolidation at the upper lobe (yellow arrow). Multiple enlarged lymph nodes are visible (blue arrow).

Microscopic findings

Sections from the lung tissue showed changes of acute lung injury, most likely of a diffuse alveolar injury type. These changes were bronchiolocentric, along with oedematous airway mucosa and sloughing of the bronchial epithelium. Peribronchial organization was also seen. The whole lung parenchyma's blood vessels were congested, however there was no thrombosis or embolus seen. The alveoli spaces showed presence of abundant foamy macrophages (Fig. 2A). These foamy macrophages were also seen occasionally within the interstitium. The alveoli also showed hyaline membrane formation, type 2 pneumocytes hyperplasia and alveolar wall thickening with oedema and infiltration by mainly lymphocytes (Fig. 2B, C & D). In one focal area, foreign body material was seen via polarized light microscopy, and it was mainly associated with the interstitial foamy macrophages. However, there were no features of lipoid pneumonia seen. An interesting finding of eosinophilic infiltration was observed, showing eosinophils scattered within the areas of acute lung

injury (Fig. 2E). The eosinophilic infiltrates were also present within the oedematous and inflamed airways. Sections of other internal organs were unremarkable.

Correlating the clinical history, autopsy findings and the laboratory investigations results, the cause of death was certified as e-cigarette associated lung injury. In essence, the mechanism of death was acute respiratory failure due to EVALI.

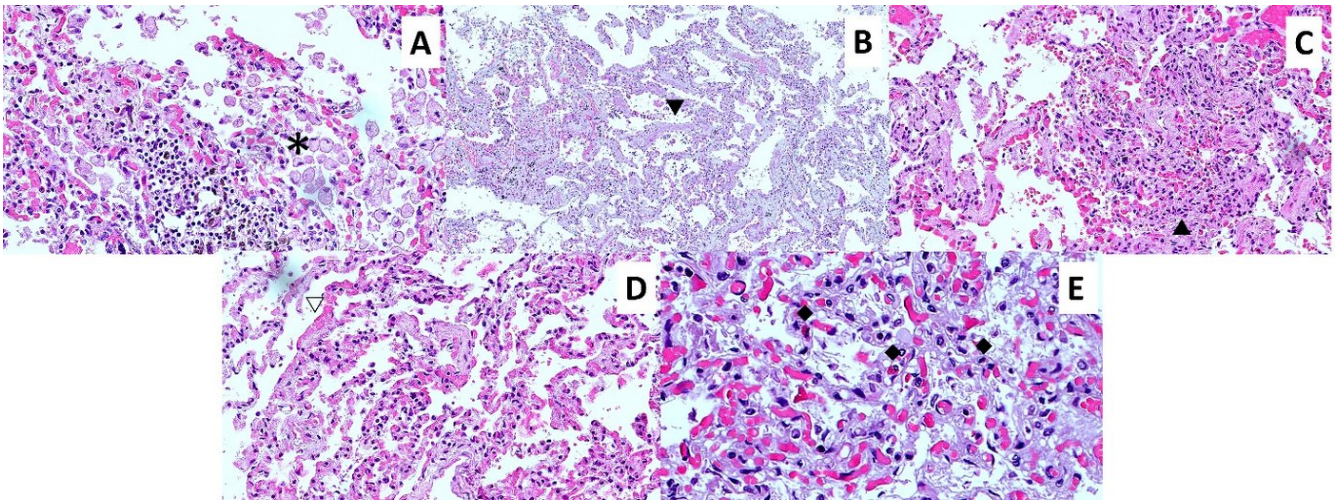

Fig. 2 : Histopathological features of diffuse alveolar injury seen in this case; A Alveolar foamy macrophages (*), B Diffuse alveolar wall thickening (▼), C Type 2 pneumocyte hyperplasia (▲), D Alveolar hyaline membranes (▽) and E Presence of eosinophilic infiltrates (◆).

Discussion

Embracing a new trend, slightly lower cost than cigarettes, diverse flavours, perceived safety, and curiosity perhaps make the e-cigarette use or vaping popular among adolescents and young adults in Malaysia, just as abroad. A local study by Komathi et al in 2015 showed that the higher prevalence was seen in users aged 18 to 34 years old.[11] Another study by Norny Syafinaz et al in 2016 showed that majority of users aged 25 to 44 years old, with males and Malays made up the characteristic profile of vape users in Malaysia.[12] The use was largely limited to cigarette smokers or ex-smokers, similar to the users in the United Kingdom. In the USA, it was reported that 21% of the school students used e-cigarettes in 2018.[13]

From the time EVALI was first identified in 2019 until 18 Feb 2020, there were 2807 confirmed cases and 68 deaths in the USA.[7] The CDC provides case definition for EVALI which includes the following: 1) using an e-cigarette within 90 days before the onset of symptoms; 2) presence of pulmonary infiltrates such as opacities on plain CXR or ground glass opacities on chest CT; 3) no evidence of infection identified via culture or PCR (confirmed case), or infection was not tested or determined to be the sole cause of lung injury (probable case) and; 4) no alternative of plausible diagnoses.[3,7] EVALI patients generally had gradual onset of symptoms over days to weeks. The symptoms include cough, chest pain and shortness of breath. Gastrointestinal symptoms may also be present, such as abdominal pain, nausea, vomiting and diarrhoea. Systemic symptoms may include fatigue, fever, and tachycardia, with tachypnea and hypoxaemia observed during the hospital admission.[7]

Major microscopic pathological findings in EVALI include hyaline membranes of diffuse alveolar damage with a significant background of interstitial oedema. Acute fibrinous and organizing

pneumonia may be present, characterized by abundant fibrin in the alveoli.[3] Varying degrees of foamy lipid-laden macrophage accumulations are usually seen, along with nonspecific inflammation and interstitial pneumonitis.[14]Marked accumulations of macrophages with distended and foamy cytoplasm is frequently encountered.[3]The frequent findings of foamy macrophages may suggest the injury is a result of the inhalation of aerosolized oils from the e-cigarette liquid.[14] Other common features include fibroblast plugs, mild chronic inflammation, fibrin membranes, fibrinous exudates and type 2 pneumocyte hyperplasia.[14] In one case report, giant cell pneumonia was also reported. [3]

The varieties of histologic features of EVALI produce several differential diagnoses, including infection, connective tissue disease, adverse drug or toxin reaction, acute eosinophilic pneumonia, diffuse alveolar haemorrhage, foreign body aspiration, subacute hypersensitivity pneumonitis, and lastly, idiopathic disease.[3] Although the microscopic findings of EVALI are non-specific, the predominant pattern of acute lung injury is the most consistent feature seen in all studies.[14]

In this case report, the most outstanding histological finding is the prominent presence of foamy macrophages, both in the alveoli as well as the interstitium. While its presence is usually associated with foreign body material, as evident with polarized microscopy, however, there is no multi-nucleated giant cell seen. Other pathological findings in this case are also consistent with previous reports, demonstrating hyaline membrane formation, type 2 pneumocytes hyperplasia and thickened alveolar wall. It is worthy to note, this case shows eosinophilic infiltration within the acute pulmonary lesions, as well as the oedematous and inflamed airways. This finding has not been reported in previous literature.

The deceased in this case was an adult male subject with history of vaping for the past five years. According to the spouse, he was an avid vape user. The respiratory symptoms were present and noticeable by the spouse, as he had been experiencing on and off shortness of breath and chest pain for the past one year. However, he refused to seek medical treatment and instead, continued the vaping habit. Approximately two weeks prior to his death, the chest pain and discomfort worsened, and he eventually succumbed to EVALI.

Conclusion

In this case report, we wished to demonstrate the autopsy and histopathological findings associated with vaping. As EVALI is real, we hope that more awareness campaigns can be coordinated to educate the youths about its irreparable damage to the lungs.

Declarations

Ethics approval and consent to participate

We seek for waiver of ethical review and approval since the data were not directly indicative of the individual subject, observatory in nature and the research involved no risk to the deceased subject.

Consent for publication

Not applicable

Competing interests

The authors declare that they have no competing interests

Funding

Not applicable

Authors' contributions

All authors contributed substantially to the analysis and interpretation of the patient data.

Razuin Rahimi led the drafting of the manuscript. Nur Hidayah Shamsuddin and Farah Lyna

Darwin Egyptoman Darwin contributed to the case presentation and the write-up of the autopsy findings. Norizal Mohd Noor was responsible for the histopathology section and the preparation of accompanying photographs. All authors reviewed the manuscript critically for important intellectual content and approved the final version.

Acknowledgements

The authors would like to thank the Director General, Ministry of Health Malaysia for the kind permission to publish this manuscript.

References

1. Institute for Public Health (IPH). *Tobacco and e-cigarette survey among Malaysian adolescents (TECMA)*. Kuala Lumpur: Ministry of Health Malaysia; 2016.
2. Essa A, Macaraeg J, Jegan N, et al. Review of cases of e-cigarette or vaping product use-associated lung injury (EVALI) and brief review of the literature. *Case Rep Pulmonol.* 2020;2020:1090629. PMID: 32607271
3. Smith ML, Gotway MB, Alexander LEC, Hariri LP. Vaping-related lung injury. *Virchows Arch.* 2020;477:167–174. PMID: 33106908
4. Cedano J, Sah A, Cedano-Mendoza R, Fish H, Remolina C. Confirmed e-cigarette or vaping product use-associated lung injury (EVALI) with lung biopsy: a case report and literature review. *Respir Med Case Rep*. 2020;30:101122. PMID: 32577363
5. Salzman GA, Alqawasma M, Asad H. Vaping-associated lung injury (EVALI): an explosive United States epidemic. *Sci Med*. 2019;116(6):492–496. PMID: 31911735
6. Cherian SV, Kumar A, Estrada-Y-Martin RM. E-cigarette or vaping product-associated lung injury: a review. *Am J Med*. 2020;133:657–663. PMID: 32179055
7. Shinbashi M, Rubin BK. Electronic cigarettes and e-cigarette/vaping product use-associated lung injury (EVALI). *Pediatr Respir Rev*. 2020;36:87–91. PMID: 32653465
8. Works K, Stack L. E-cigarette or vaping product use-associated lung injury (EVALI): a case report of pneumonia mimic with severe leukocytosis and weight loss. *J Am Coll Emerg Physicians Open*. 2020;1:46–48. PMID: 33000013
9. Ansari-Gilani K, Petraszko AM, Teba CV, et al. E-cigarette use-related lung disease: review of clinical and imaging findings in three cases. *Clin Imaging*. 2020;49:139–143. PMID: 32008808
10. Ministry of Health Malaysia. *Clinical practice guidelines: management of e-cigarette or vaping product use-associated lung injury (EVALI)*. Putrajaya: Ministry of Health Malaysia; 2021.
11. Perialathan K, Rahman AB, Lim KH, et al. Prevalence and associated factors of ever use of electronic cigarettes: findings from hospitals and health clinics study based in Malaysia. *Tob Induc Dis*. 2018;16:55. PMID: 31516452

12. Abdul Rahman NS, Nik Mohamed MH, Ab Rahman J, et al. Characteristics of e-cigarette or vape users and patterns of use: Malaysian chapter. *Med J Malaysia*. 2017;72(Suppl 1):53.
13. Tee GH, Low WY. Electronic cigarettes use among adults and adolescents in Malaysia: a public health concern? *Asia Pac J Public Health*. 2019;31:1–3. PMID: 31595768
14. Youmans AJ, Harwood J. Gross and histopathological findings in the first reported vaping-induced lung injury death in the United States. *Am J Forensic Med Pathol*. 2020;41:1–4. PMID: 31977349

What's New in This paper

What is already known on this topic?

Vaping-associated lung injury (EVALI) has been increasingly reported worldwide, predominantly in young adults, with clinical presentations ranging from mild respiratory symptoms to acute respiratory failure. Most published data focus on clinical, radiological, and epidemiological findings, while detailed autopsy-based pathological descriptions remain limited.

What question did this study address?

This study addressed whether fatal vaping-induced lung injury could be definitively characterized at autopsy and histopathological examination, and how post-mortem findings correlate with clinical and radiological features in a Malaysian context.

What does this study add to our knowledge?

This report provides one of the first detailed autopsy-confirmed cases of fatal vaping-induced lung injury in Malaysia. It highlights the value of post-mortem examination in establishing the cause of death, demonstrates key histopathological lung features associated with vaping exposure, and diagnostic challenges in distinguishing EVALI from other causes of acute lung injury during life.

Suggestions for further development

Further studies involving larger case series or registry-based surveillance are needed to better define the pathological spectrum of vaping-associated lung injury. Correlation between specific vaping substances, toxicological findings, and histopathological patterns would strengthen causal inference and support public health and forensic decision-making.